COLUMBIA LIBRARIES OFFSITE
HEALTH SCIENCES STANDARD
HX64085929
QM541 .P85 Topography of the th
RECAP

QM541 P85

Columbia University
in the City of New York

College of Physicians and Surgeons

Library

1

TOPOGRAPHY OF THE THORAX AND ABDOMEN

Digitized by the Internet Archive
in 2010 with funding from
Columbia University Libraries

http://www.archive.org/details/topographyofthor00pott

VOLUME I SCIENCE SERIES NUMBER 1

THE UNIVERSITY OF MISSOURI STUDIES

TOPOGRAPHY OF THE THORAX AND ABDOMEN

BY

PETER POTTER

Associate Professor of Anatomy St. Louis University sometime Instructor in Anatomy University of Missouri

PUBLISHED BY THE
UNIVERSITY OF MISSOURI
August, 1905

QM541
P85

Copyright 1905, by
THE UNIVERSITY OF MISSOURI

COLUMBIA, MO.:
E. W. STEPHENS PUBLISHING CO.
1905

PREFACE

This paper is the revised and enlarged form of a thesis presented to the University of Missouri in June, 1903, for the degree of Master of Arts; and is based upon work begun in the anatomical laboratory of the University of Missouri in 1901.

The object of the paper is to add to the few detailed observations upon the interrelations of the organs as found in a single body.

For this purpose, therefore, a body has been studied by the method of sections, with reference to the more important thoracic and abdominal organs and systems which are described individually, giving in each case the topography of the part, its relations to surrounding structures, and a comparison with the literature of the subject. Although no attempt has been made to exhaust this literature, reference is made constantly to the text-books of descriptive anatomy, by Quain, Cunningham, Testut, Bardeleben, and Poirier and Charpy; the anatomical atlases of Braune, Toldt, Spalteholtz, Bardeleben and Haeckel; and the topographical anatomies of Joessel, Merkel, Hyrtl, and Ruedinger, and special articles and monographs by Henke, Toepken, Schiefferdecker, Addison and others. After each discussion, there is indicated, briefly, the more important points of difference between the relations of the organs found in the trunk described in this paper and those described by the authors named.

I have been at all times greatly assisted by the advice of Dr. C. M. Jackson, under whose direction the work was commenced and who has untiringly aided until its completion.

I am also under obligations to Dr. A. C. Eyclesheimer, of St. Louis University, Dr. D. D. Lewis, of the University of Chicago, and to Dr. L. F. Barker, of the Johns Hopkins University, for many helpful suggestions and encouragement.

I am greatly indebted to Mr. Roy Dimmitt, superintendent of Manual Arts, Birmingham Public Schools, Birmingham, Alabama, for lettering the plates; and to Mr. Alfred Streedain, artist to the department of Anatomy, St. Louis University, for lettering the projections.

TABLE OF CONTENTS

CHAPTER		PAGE
Introduction		1
Material and Methods		5
Topography of the Organs		
	Skeleton	12
	Lungs	15
	Trachea	25
	Heart	27
	Aorta and Venae Cavae	34
	Oesophagus	37
	Stomach	38
	Duodenum and Jejunoileum	41
	Large Intestine	43
	Liver	48
	Pancreas	54
	Spleen	56
	Kidneys	57
	Ureters and Bladder	60
	Suprarenal Glands	61
	Thyreoid Gland	62
Table of Levels		63
Table of Structures Found at Various Levels		65
Plates		69

TOPOGRAPHY OF THE THORAX AND ABDOMEN

INTRODUCTION

THE use of sections in the study of human topographic anatomy can be traced back for several centuries. They were used to illustrate the works of Vesalius (1555), Eustachius (1564) and numerous anatomists of the seventeenth and eighteenth centuries. These illustrations consist chiefly of crude and schematic representations of head and pelvic sections.

De Riemer,[1] a Dutch anatomist, made sections of the frozen body in 1803 and published his atlas in 1818.

Froriep,[2] of Tübingen, made sections of frozen arms and legs in 1813 and of frozen female pelves in 1815. He announced as his most striking observation "the entirely new view of the relations of the parts given by the method." This view was so different from that obtained by the ordinary methods of study that he states: "It is necessary for one to feel one's way, as it were, among the parts."

[1] De Riemer, P., Exposition de la position exacte des parties internes du corps humain, tant par rapport à leur position mutuelle, que par leur contact aux parois des cavités ou elles se trouvent placées; avec une description explicative y relative. La Haye, 1818.

[2] Froriep, Ludwig Friedrich V., Ueber anatomie in beziehung auf chirurgie. Nebst einer darstellung der relativen dicke und lage der muskeln am ober-und unterschenkel. Weimar, 1813. Ueber die lage der eingeweide im becken, nebst einer neuen darstellung derselben. Weimar, 1815.

Pirogoff,[3] a Russian surgeon and anatomist, reinvented the method of frozen sections and used it very extensively. His work, in five large volumes, contains over 200 figures of sections through various parts of the body, illustrating both normal and pathological conditions.

Braune,[4] a German anatomist, used the method of frozen sections in his study of topographic anatomy. While his atlas is less extensive than that of Pirogoff it is far more accurate and his colored lithographic plates are (to this day) the best reproduction of sections through the human body.

I have not given the names of all of the workers along this line but have only indicated the main steps in the development of the use of sections in the study of topographic anatomy. Even though this method has been in use for several centuries it was not until recently that any marked advance was made. Each worker, when he first began the use of sections, expressed surprise at the great difference between the impressions obtained from the ordinary methods of study and those obtained from a study of sections. Yet many of these workers disregarded the results to be derived from the study of their sections and held to their ideas derived from other sources. In some instances the reproductions of the sections show wide deviations from the statements in the text.

It was not until Henke[5] suggested the construction,

[3] Pirogoff, Nicolas, Anatome topographica sectionibus per corpus humanum congelatum triplici directione ductis illustrata. Petropoli, 1852-9.

[4] Braune, W., Topographisch-anatomischer atlas. Nach durchschnitten an gefrorenen cadavern. 3 Aufl. Leipzig, 1886-8.

[5] Henke, W., Construction der lage des herzens in der leiche aus einer serie von horizontalschnitten. Tübingen, 1883.

from sections, of charts showing the positions of the organs of the body that there was any advance beyond what Froriep had announced nearly seventy years before.

Henke's method is, briefly, to establish a vertical line, representing the median sagittal plane of the body, crossed by horizontal lines representing the positions of the sections from which the projection is to be made. Any point in any section can be accurately projected upon the chart by using the vertical line and the proper horizontal line as coördinates.

This method of recording observations marks the beginning of a new epoch in topographic anatomy, because it puts each part into a concrete form and thus lessens the liability of error. At the present time, all writers on topographic anatomy give the section method a prominent place as a method of study.

Not only has the method of recording observations changed but also the method of preparation of the sections. The original method (that used by all the anatomists referred to) was to freeze the body thoroughly and while frozen to saw it into sections of the desired shape and thickness. The sections were then placed in strong alcohol and allowed to thaw slowly. The results were not entirely satisfactory since the organs did not always become sufficiently firm to retain their exact form and relations, and the shrinkage was unequal in the different organs. Moreover the surfaces were somewhat rough from the sawing so that it was difficult to recognize the finer structures.

A distinct step in advance was made when formalin, as a hardening reagent, was introduced into the methods of

preparation. It was first employed, by F. Blum,[6] in microscopic technique and afterwards by Gerota in topographic anatomy. Gerota[7] suggested the injection of a five per cent solution of formalin into the arteries and the sectioning of the frozen body in the usual way. Jackson[8] has recently and independently shown that by the use of a fifty per cent solution of formalin it is not necessary to freeze the body before sectioning. The advantages of this method are that the organs, hardened in the exact form and position they were in at the time the body was injected, do not change after the sections are made; all parts except the bones can be cut with a knife, thus giving smooth, even surfaces. It is also possible to decalcify after hardening with formalin, but this is seldom necessary or desirable.

[6] Blum, F., Das formaldehyd als härtungsmittel. Vorläufige mitteilung. Zeitschrift f. wiss. mikroskopie, Bd. 10. 1893.

[7] Gerota, D., Ueber die anwendung des formols in der topographischen anatomie. Anat. anzeiger, Bd. 11. 1895.

[8] Jackson, C. M., A method of teaching relational anatomy. Journal of the american medical association, 1901.

MATERIAL AND METHODS

The sections upon which this paper is based were made, according to Jackson's method, from the body of a negro man about thirty years of age, six feet in height and about one hundred and ninety pounds in weight. The body was well proportioned, the muscles were well developed, there was no surplus fat and no external signs of abnormal or pathological conditions. Just after a full meal the man died from asphyxia while cleaning an old well. The body came into the anatomical laboratory of the University of Missouri a few hours after death and was at once injected, through the femoral artery, with about six quarts of fifty per cent formalin (twenty per cent formaldehyde).[1] Care was taken to have the body straight (in the dorsal position) and the limbs in their normal position. Within twelve hours after being injected the entire body was perfectly rigid. A few weeks later the trunk was cut into twenty-five cross-sections with a long knife and saw. It was the intention to have each cut pass through an intervertebral disc but this was not accomplished in every case. The surfaces of the sections should have been horizontal and parallel to each other, but those through the upper part of thorax are lower and thinner in front than behind. As each section was made the loose pieces and parts liable to be displaced were stitched in place with needle and thread. The body was so thor-

[1] A small quantity of a weak formalin solution had already been injected into the peritoneal cavity by an undertaker. This causes the abnormal dilatation of the peritoneal spaces seen between the organs in the abdominal sections.

oughly hardened that each organ shows the impressions made upon it by the adjacent organs and retains its form even though it is cut into relatively thin sections. The main structures in each section were identified without disturbing the relations of the parts.

While every part was yet in its normal position, a drawing was made of each section by placing a thin plate of glass on its upper surface and tracing the outline of the parts with a fine pen and India ink. The tracing was readily transferred to paper by placing the sheet on the glass over the drawing, holding them up to the light and retracing the outline on the paper. In making the tracings each line was drawn with the eye and pen directly over the same part, thus avoiding displacement on account of the thickness of the glass.

For the purpose of uniformity and in order to avoid unnecessary confusion all the plates represent the section as viewed from above with its posterior portion toward the top of the page.[2]

After the permanent outline records of the undisturbed parts had been thus obtained each section was studied in minute detail. Every part was followed from its beginning to its end through every section in which it appears. Vessels and other hollow structures were traced by passing a bristle through the lumen. Nerves, muscles, tendons, and all solid structures were traced by dissecting the connective tissue away from one side of each so that they could be followed through the section and definitely located in the next section.

[2] Jackson, C. M., Orientation of figures in topographical anatomy. nat. anzeiger, Bd. 20. 1901, s. 300.

In order to avoid errors, each plate was finished with the section from which it was taken before me. No attempt has been made to reproduce the parts in their natural colors or appearances. All finishing lines are more or less conventional and only attempt to give sufficient contrast so that the parts may be readily distinguished.

The bones are indicated by a central stippled area representing the cancellous bone, surrounded by a clear area representing the compact bone. The intervertebral discs and costal cartilages are white. The muscles are lined in one direction only, with the exception that the diaphragm and the walls of the heart are cross-lined. The arteries are red and the veins blue as are also the corresponding parts of the heart. The cavities of the body are black, except for a narrow white line around the boundary of each space. The nerves appear as circles. The spinal cord contains the sign H. The liver is lined with lines oblique to those of the muscles. The spleen and some of the lymph glands are filled in by circles. The lungs, thyreoid gland and pancreas are represented as composed of angular spaces. The irregular line in the suprarenal gland represents the medulla of the gland. The kidney shows the radiate appearance of the medullary substance. The ureter is shown as a small double walled tube with its inner wall wrinkled. The vas deferens is also double walled but the inner circle is very small. The sections of the alimentary canal are outlined only. The outer line represents the peritonaeal coat, the inner line the mucous coat and the interspace the remaining layers.

In a few sections uncut parts which lie near enough to the surface of the section to make it desirable to indicate

their position are shown in the plates in dotted outlines.

The projections were made from careful measurements of the organs at the surface of the several sections. The measurements were made by means of a plate of glass, the surface of which was ruled with parallel lines 1 cm. apart. The center line and every fifth line was colored to facilitate the reading.

The ruled surface of the glass was placed upon the drawing so that the lines would be in immediate contact with the parts to be measured. To exclude errors, a duplicate set of measurements was taken in the same way directly from the sections. For projections upon the anterior and posterior surfaces of the body the middle line of the glass was always placed over the anteroposterior midline of the plate. This midline of the section was taken as a line through the middle of the sternum or linea alba anteriorly and the center of the centrum or intervertebral disc posteriorly. It does not pass through the spinous process in those cases where the latter is displaced to the right or left as sometimes happens.

The midline thus established was taken as the zero line of the section and the measurements were made to the right and left with it as the line of reference. Since the projection could only show the outline of an organ the point nearest the midline and the one farthest from the midline were the two measured. Where an organ crossed the midline, the points representing the two lateral extremities were taken. The same measurements were used for both projections. In the case of the lungs, however, two sets of measurements were taken, one for the anterior projection and the other for the posterior. The anterior margins and

external surfaces were taken for the anterior projection (Plate XXVIII), and the most internal portions in the region of the posterior mediastinum (crista pulmonis of Merkel[1]) and the external surfaces for the posterior projection. This difference was made to show the more direct relations of the lungs to the sternum and to the vertebral column respectively.

The points measured upon any section were located on millimeter cross-section paper, on the horizontal line representing the upper surface of that section, at distances from the zero line equal respectively to their several distances from the midline of the section. In case the plane of the section was exactly horizontal, as in Plate XI, the points so located were points through which the outline of the corresponding organs must pass. But in those cases where the anterior and posterior margins of the section were at different levels, as in Plate VI, correction had to be made for the obliquity of the plane.

By careful dissections and comparison of the sections, the outline of each organ was made as nearly accurate as possible as to shape and size. When the outlines were penciled in and had been carefully compared with the organs, they were retraced with ink in the broken lines in which they appear in the plates.

It must be remembered in examining the projections that the cross-lines represent planes which are practically parallel and that the outline of any organ at a given level is as it would appear with the eye in that horizontal plane, and not as it would appear to the eye at any point outside of the

[1] Merkel, F., Bardeleben's Handbuch der anatomie. Bd. VI. Abthl. 1.

horizontal plane. Since every point upon the outline of an organ has been projected along a horizontal line parallel to the mid-plane from its position on the organ to the (anterior or posterior) surface of the body, it is necessary in order to see that point in its correct relations, to imagine that the eye is in the line of projection. The position of the eye must change, therefore, for every object viewed, and the projections do not represent exactly what would be seen if the body were transparent and viewed from a single point.

The nomenclature adopted by the German Anatomical Society at its meeting in Basel, 1895 [BNA] is used in Plates I to XXV. The intervertebral discs are designated by Roman numerals; the number in each case corresponding with the vertebra above.

The following topographic lines and directions are used:

The midline of a section is a line passing through the middle of the sternum or linea alba anteriorly and the center of the body of the vertebra posteriorly. The midplane of the body is a vertical plane which contains the midlines of the sections. Upon the anterior surface of the body this plane would appear as a line passing through the middle of the sternum and the linea alba (anterior midline "OO," Plate XXVIII) and upon the posterior surface as the posterior midline ("OO," Plate XXIX).

The midclavicular line is a vertical line through the middle of the clavicle, as seen in projection. It is about 8 cm. from the midplane.

The midaxillary line is a vertical line through the apex of the axilla when the arm is in its normal position ("OO,"

Plates XXX and XXXI). The plane connecting the two midaxillary lines is the midaxillary plane.

The terms right and left are used as applied to the body of the subject and not to that of the observer, e. g. the apex of the heart is on the left side of the subject and opposite the right side of the observer.

The term section refers to one of the parts into which the body is cut. A section is located by the level of its upper surface, as section X is through the seventh thoracic vertebra posteriorly and the third intercostal muscles anteriorly because in making this section these structures were cut by the knife and saw.

TOPOGRAPHY OF THE ORGANS

THE SKELETON

The vertebral column is about 4 cm. wide in the upper thoracic region. It decreases very slightly down to the middle of the thoracic region. From here downward it increases gradually until it is over 6 cm. wide at the sacrum. There is a gradual increase in the thickness of the centra. The first thoracic centrum is 1.5 cm., the third lumbar centrum is 2.7 cm. thick. The fourth and fifth lumbar centra are about the thickness of the first and second. The intervertebral discs correspond in width and thickness to the centra. The disc between the first and second thoracic vertebrae is only .5 cm. in thickness, while that between the third and fourth lumbar vertebrae is 1.2 cm., in thickness. The fourth and fifth lumbar discs are about the same thickness as the first and second. When seen from the side (Plates XXX and XXXI) the vertebral column is S-shaped. On account of a slight kyphosis the convexity in the upper thoracic region is a little greater than usual. For this same reason the spinous processes of the first three thoracic vertebrae are nearly horizontal.

The **sternum** extends from the level of the upper part of the third to the level of the lower part of the eleventh thoracic vertebra. The sternal angle is at the level of the lower border of the fourth thoracic vertebra. The **gladiolus** extends from the lower border of the fourth to the middle of the ninth thoracic vertebra. The **xiphoid process** is

diamond-shaped and is located anterior to the lower half of the ninth and the tenth and eleventh vertebrae. It is inclined to the right of the midline, and is more firmly attached to the cartilage of the right seventh rib than to the gladiolus.

The **costochondral articulations** from the first to the tenth, lie in a straight line, oblique to the midline, which (in projection) is about 5 cm. from the midline at the first rib and about 13 cm. at the tenth rib. The **subcostal angle** is about 70°. The sternal ends of the **clavicles** are in front of the second thoracic intervertebral disc and the upper half of the third vertebra. The **scapula** extends from the fifth cervical intervertebral disc to the lower part of the seventh thoracic vertebra. The glenoid cavity is opposite the first thoracic vertebra.

The highest point of the **crest of the ilium** is at the level of the fourth lumbar vertebra. The **tip of the coccyx** reaches the level of the middle of the symphysis pubis and the upper border of the great trochanters of the femur.

The right nipple is over the fifth rib. The left one is partly over the fifth rib and partly over the fourth intercostal space. Each one is about 11 cm. from the midline. The umbilicus is in front of the upper half of the fourth lumbar vertebra.

The majority of the texts consulted give insufficient data on the topography of the skeleton for a very satisfactory comparison. I believe, however, that the anterior thoracic wall is relatively low in this subject. The manubrium is more than 1 cm. below where it would be if found at the lower part of the second thoracic vertebra, as stated by Cunningham[1],

[1]Cunningham, D. J., A text book of anatomy. New York, 1903.

Poirier and Charpy[1], and Mehnert[2]. According to Mehnert, who has made a careful study of the topography of the thoracic organs, the upper border of the sternum in adults usually corresponds to the second thoracic vertebra or to the disc below. Occasionally it reaches the third as in this case. It is probable that the bending forward of the upper thoracic portion of the vertebral column has forced the manubrium down to the level of the third vertebra.

There seem to be several differences between the projections given by Hermann and Ruedel[3] and those given in this paper. But no definite conclusions can be drawn from their projections since they have not projected the skeleton and viscera in the same figure. There are no descriptions of the projections nor any explanation as to how they were made. Moreover the projections themselves do not appear to be very accurate. I made careful tracings of their projection of the skeleton upon the anterior surface of the body and placed it over the corresponding projections of the viscera. I found that the parts common to the projection of the skeleton and that of the organs (i. e., the cross-lines indicating the position of the surfaces of the sections, the body outline, the clavicles, the sternum and the subcostal angle, which are found in both projections) do not coincide as they should. Their table of levels may therefore be taken as of more value than their projections, and will be referred to as the various organs are discussed.

[1]Poirier, P. et Charpy, A., Traité d'anatomie humaine. I. Paris, 1899.

[2]Mehnert, E., Ueber topographische altersveränderungen des atmungsapparates. Jena, 1901.

[3]Hermann, F. und Ruedel, O., Die lage der eingeweide. Erlangen, 1895.

THE LUNGS

The lungs appear in Plates V to XIII and XXVIII to XXXV. While the left lung is adherent to the pleural wall throughout, its substance seems to be perfectly normal. The **apex** of the right lung is about 2 cm. and that of the left lung about 2.5 cm. above the upper border of the middle of the inner third of the clavicle, on a level with the middle of the first thoracic vertebra 3.5 cm. from the midline. By projecting up into the neck each apex comes into relations with the structures above the clavicle. The eighth cervical nerve and the lower trunk of the brachial plexus cross it from above outward and forward, while the sympathetic cord and inferior cervical ganglion rest upon it internally. The vertebral and ascending cervical vessels lie upon the anterior part of the pleural dome in their passage upward into the neck. The arch of the thoracic duct is separated from the left apex by these vessels (Plate IV). The subclavian artery arches across the apex less than 1 cm. from its highest point and separates the lung from the scalenus anterior muscle and the internal jugular vein. The innominate vein lies just below the subclavian artery and separates the lung and sternoclavicular articulation. When seen in anterior projection the apex of each lung is overlapped by the lower part of the corresponding lateral lobe of the thyreoid gland (Plates XXVIII and XXXII). The two organs are not in contact however (Plates XXX, XXXI, XXXIV and XXXV). The apex of the lung comes nearly to the surface of section IV in the quadrilateral space in front of the neck of the first rib where it is 6 or 7 cm. from the anterior surface of the neck and where it is separated from the thyreoid gland by the vertebral and ascending cervical vessels, and the internal part of the carotid sheath

containing the common carotid artery. On the left side the thoracic duct is along with the ascending cervical vessels.

If a needle were inserted directly backward through the middle of the sternal head of the sternomastoid about 2 cm. above the clavicle it would enter the highest part of the apex of the lung. The needle would pass through the skin, platysma and sternomastoid muscles between the internal jugular vein and the thyreoid gland, through the common carotid artery and into the space containing the vertebral and ascending cervical vessels. On the left side it would pierce the thoracic duct. In each case the highest part of the apex lies a little internal to the interspace between the two heads of the sternomastoid.

The **anterior border of the right lung** is very indistinct above but is more plainly marked below. From the apex it passes downward behind the upper border of the sternum a little internal to the sternoclavicular articulation, and remains behind the right half of the sternum down to the sixth sternochondral articulation, where it becomes continuous with the inferior margin of the lung (Plates XXVIII and XXXII). The **anterior border of the left lung** is more plainly marked above than that of the right. It is deeply concave below where the heart encroaches upon this lung more than upon the right one (Plates XXVIII and XXXII). Beginning at the apex the anterior border may be traced downward and inward behind the left sternoclavicular and first sternochondral articulations. It passes to the left of the sternum in the first intercostal space and runs downward and outward to the middle of the fourth intercostal space in the midclavicular line. Here it turns inward, crosses the fifth rib 1 cm. internal to the midclavicular line and becomes

continuous with the inferior margin of the lung in the fifth intercostal space.

The **posterior border** (or posterior surface) of each lung is separated from the corresponding internal surface by a ridge—**crista pulmonis** of Merkel—more plainly seen above the hilus than below it (Plates VI and VII). The crista of the right lung (seen in projection in Plates XXIX and XXXIII) lies anterior to the right half of the vertebral column from the second to the ninth thoracic vertebra. It becomes continuous with the posterior part of the inferior margin opposite the disc between the ninth and tenth vertebrae. The crista of the left lung lies a little farther from the midline and extends down to the side of the tenth vertebra where it turns outward to join the inferior margin in the tenth intercostal space, at the level of the disc between the tenth and eleventh vertebrae.

The **external surface** of each lung is convex in all directions and presents a regular curve from apex to base which follows the concave internal surfaces of the thoracic wall. These surfaces are crossed by oblique grooves which are the external limits of the fissures dividing the lungs into lobes. The lines in the projections indicating these fissures represent them as seen on the surfaces of the lungs. It must be borne in mind that the relations of a fissure to the ribs when seen from the front or back (Plates XXVIII, XXIX, XXXII and XXXIII) do not correspond exactly to those when seen from the sides, (Plates XXX, XXXI, XXXIV and XXXV).

The **great fissure of the right lung** begins behind, opposite the centrum of the fourth vertebra, between the spines of the third and fourth vertebrae, passes outward under cover of the fifth rib to cross the midaxillary line in the fifth intercostal space and ends in the inferior margin of

the lung in the sixth intercostal space, about 1.5 cm. external to the midclavicular line. The **horizontal fissure** begins in the great fissure just posterior to the midaxillary line and runs inward and a little downward behind the third intercostal space to end in the anterior margin of the lung behind the fourth sternochondral articulation. The **great fissure of the left lung** begins behind, a little higher than that of the right lung. It is, at first, at the level of the disc between the third and fourth vertebrae and runs downward and outward across the fourth intercostal space and the fifth rib to cross the midaxillary line in the fifth intercostal space. Here it takes a more vertical direction and ends in the inferior margin of the lung at the upper border of the sixth rib a little external to the midclavicular line. A very narrow strip of the external part of the inferior lobe is seen, in the anterior view, near the outer part of the base of each lung. The remainder of the lung seen in anterior view is formed by the superior and middle lobes on the right side and the superior lobe on the left side (Plates XXVIII and XXXII). Posteriorly, the upper third is formed by the superior lobe in each case, while the remainder is formed by the inferior lobe.

The **internal surface** of each lung, which also extends from apex to base, is shorter and more irregular in contour than the external surface. It is concave in all directions. The concavity is more marked from before backwards than from above downwards, and in the lower two-thirds than in the upper third. That of the left lung is much more marked than the right (Plates X, XI, XII, XXVIII and XXXII). For convenience of description the internal surface of each lung may be divided into four areas. The first area may be made to include the hilus, the second, the region above the hilus, corresponding to the superior media-

stinum, the third, posterior to the hilus, corresponding to the posterior mediastinum, and the fourth, anterior to the hilus, corresponding to the middle and anterior mediastinum.

The hilus is an area roughly oval in outline, much nearer the posterior than the anterior part of the middle of the inner surface of the lung, through which the root structures pass from the mediastinum to the lung. The **root of the right lung** begins above at a plane passed through the first intercostal space and the lower part of the fourth thoracic vertebra, and ends below at a plane passed through the upper part of the fourth sternochondral articulation and the lower border of the seventh thoracic vertebra. It lies between the vena cava superior and right auricle anteriorly and the vena azygos major and oesophagus posteriorly. The arrangement of the three main structures forming the root, from above downward is bronchus, artery, vein. The artery lies in a plane anterior to the bronchus and directly over the vein. The vena azygos major arches over the bronchus and empties into the vena cava superior opposite the middle of the fourth thoracic vertebra. The root is covered with pleura reflected from the mediastinum onto the inner surface of the lung. Anteriorly the reflection is from the vena cava superior to the pulmonary artery above and from the pericardium, at the level of the auricula, to the pulmonary vein below. Superiorly the pleura passes from the side of the trachea over the right bronchus onto the lung. The arch of the vena azygos major lies directly under the pleura covering this part of the root. Posteriorly the reflection is from the vena azygos major, except in the uppermost part, where that vein lies in the posterior part of the root. Here the reflection is from the side of the oesophagus. Inferiorly the pleura covering the

root is prolonged downward from the pulmonary vein to the diaphragm, forming the ligamentum pulmonale connecting the inner surface of the lung to the mediastinal wall, (Plates XI, XII).

The **hilus of the left lung** is shorter and wider than that of the right lung. It extends from the lower border of the fourth to the lower border of the sixth thoracic vertebra. The **root structures** are in relation anteriorly with the pericardium over the left auricle, and posteriorly with the descending aorta and the oesophagus.

The aorta arches over the root of the left lung and lies in contact with the bronchus and the pulmonary artery. The bronchus, artery, and vein do not bear the same relation to each other as in the root of the right lung. The bronchus is above at first but in its downward course to pass under the arch of the aorta it also passes behind and below the pulmonary artery. The pulmonary vein lies below the artery but more anterior to it than on the other side. On the right side these structures are bronchus, artery, vein, from above downward; on this side they are more nearly bronchus, artery, vein, from before backward. On account of the pleural adhesions of this lung, it is difficult to determine the reflections of the pleura over the hilus.

In the **region of the superior mediastinum** the right lung is in relation with the trachea and oesophagus, and with the vena cava superior from its formation behind the first sternochondral articulation down to the right auricle. The crista pulmonis projects into the space between the oesophagus and the vertebral column. The vena cava superior makes a slight impression upon the lung near the anterior part of this surface. The innominate artery is in relation with this surface of the lung from the arch of the aorta

up to where its subclavian branch arches across the anterior surface of the lung. The phrenic nerve is anterior to the lung above the first rib, but below this level it is between the lung and the vena cava superior. The vagus is also anterior to the lung above but at the sternoclavicular articulation it passes inward and backward between the lung and the trachea. In this region the left lung is deeply grooved by the arch of the aorta below and the subclavian artery and vertebral vein above. The groove for the subclavian extends from that for the aorta upward to the subclavian groove across the anterior surface of the apex. The crista pulmonis is in relation in this region with the thoracic duct and oesophagus anteriorly and the vertebral column posteriorly. The left lung does not enter into close relation with the trachea but is separated from it above by the subclavian artery, and the oesophagus which lies to the left of the midplane, and below by the arch of the aorta. The vagus and phrenic nerves of this side like those of the right side are at first anterior to the lung at the apex but pass internal to it just below. On both sides these nerves pass anterior to the arch of the subclavian. The left vagus follows the anterior surface of the left subclavian artery down to the arch of the aorta, the left side of which it crosses between the pleura and the artery. The phrenic nerve lies anterior to the vagus. It is between the lung and the innominate vein above, and is embedded below, in the mediastinal wall about half way from the sternum to the vertebral column (Plates V, VI, and VII).

In the **region of the posterior mediastinum** the internal surface of the inferior lobe of each lung presents a slight impression. The vena azygos major lies in the impression in the right lung. The descending aorta makes the impression in the left lung. This impression is not as deep

as usual, and becomes less and less distinct from above downward. The oesophagus which lies a little anterior to these vessels is in contact with both lungs. It is partially separated from the left lung above by the aorta, but below where it crosses the anterior surface of the aorta it is in direct contact with this lung (Plates IX, X, XI, and XII). The lungs do not come into contact with the thoracic duct since that vessel lies between the vena azygos major and the aorta and behind the oesophagus.

In the **middle and anterior mediastinal regions** the internal surfaces of the lungs are in contact with the heart. When seen in anterior projection (Plates XXVIII and XXXII) the anterior border of the right lung overlaps the right border of the heart about 2 cm., while the anterior border of the left lung overlaps the left border of the heart less than 1 cm. at any point. All three lobes of the right and both lobes of the left lung touch the heart. The superior lobe of each lung is the only part in contact with the basal portion of the heart (Plates VIII and IX). These lobes present a triangular area in contact with the heart which may be bounded below by a line from the lower part of the sixth thoracic vertebra to the middle of the fourth sternochondral articulation on the right side and from the same vertebra to the sixth costochondral articulation on the left side. In each case this area touches both auricle and ventricle and on the left side the apex of the heart (Plates VIII to XII). The middle lobe of the right lung comes into contact with the right auricle near its upper and posterior part at the level of the disc between the sixth and seventh thoracic vertebrae and the third costal cartilage. The area covered by this lobe increases from above downward as that covered by the superior lobe decreases. At the level of the fourth car-

tilage and intercostal space it covers the anterior two-thirds of this side of the heart (Plate XI). The superior and middle lobes of the right lung together cover an area which corresponds very closely to that covered by the superior lobe of the left lung. The inferior lobe of each lung comes into contact with the posterior part of the left auricle near the disc between the sixth and seventh thoracic vertebrae. The surface of each of these lobes in contact with the heart becomes larger and larger from above downward. This is especially true of the left side where the heart encroaches more and more upon the internal surface of this lung (Plates XI and XII). The right phrenic nerve is in relation, in the superior mediastinum, with the superior lobe. About the level of the third costal cartilage it crosses the horizontal fissure and comes into relation with the middle lobe, which it crosses obliquely to reach the inferior lobe near the level of the fourth costal cartilage. It remains in contact with the inferior lobe down to its entrance into the diaphragm. The left phrenic is only in contact with the superior lobe of the left lung.

The base of each lung is deeply concave in all directions as may be seen from the height to which the dome of the diaphragm rises above the inferior margin of each lung (Plates XXVIII to XXXV). Its margin (margo inferior) is thin except internally, where it rests upon the central tendon of the diaphragm. The anterior part of the inferior margin of each lung is in the fifth intercostal space at the level of the xiphosternal articulation and the disc between the ninth and tenth thoracic vertebrae. The inferior margin of the right lung is nearly in a horizontal plane. It is behind the sixth right sternochondral articulation at the sternum, in the fifth intercostal

space in the midclavicular line, at the upper border of the seventh rib in the midaxillary line, and over the head of the tenth rib at the side of the vertebral column. The inferior margin of the left lung begins anteriorly in the fifth intercostal space near the midclavicular line and passes behind the seventh rib in the midaxillary line to end in the tenth intercostal space at the side of the vertebral column.

The base of the **right lung** is separated by the right dome of the diaphragm from the right lobe of the liver. Since the middle lobe of the lung forms the anterior part of the base it enters into relation with a corresponding portion of the right lobe of the liver. The larger posterior part of the base of the lung is formed by the inferior lobe which is in relation with the remainder of the superior and a portion of the posterior surface of the right lobe of the liver. The inner and posterior part of the base is in relation with the vena cava inferior for the very short distance that that vessel is in the thoracic cavity between the vena caval opening through the diaphragm and that into the heart. Below the caval opening through the diaphragm the lung is separated from the vena cava inferior by the diaphragm (Plate XIII). The projections show the lung overlapping the liver only about 3 cm. This condition is probably due to the lung being in a condition of extreme expiration. During inspiration the lung margin may be pushed down into the costophrenic sinus several centimeters lower than is found in this subject.

The **base of the left lung** is in relation with the left lobe of the liver, the stomach, and the spleen. The liver extends from the midline of the body outward and a little backward, filling the central portion of the left dome of the diaphragm. It is in relation with the central portion

of the base of the lung which is formed almost entirely by the inferior lobe of the lung. Since the inferior margin of the lung is below the level of the liver the peripheral portion of the base comes into relation with the fundus of the stomach from near the midclavicular line around to the vertebral column (Plates XIII, XXVIII and XXXII). The upper part of the spleen is interposed between the posterior part of the base of the lung and the posterior surface of the stomach below the level of the tenth vertebra. If the base of the lung were viewed from below, its gastric area would be roughly hourglass-shaped, being encroached upon by the liver from the front and right side and by the upper pole of the spleen from behind and the left. Plates XXVIII and XXXII show the superior lobe of the lung (in projection) in relation with the spleen but a reference to Plate XIII will show that this part of the lung is in reality separated from the spleen by a space 10 cm. in width containing the fundus of the stomach.

The lungs as found in this subject do not reach as low a level, especially upon the anterior thoracic wall, as is usually given in works on topographic anatomy. This difference is probably due to the lungs being in a condition of extreme expiration in this instance while the usual statements apply to a condition which is a mean between expiration and inspiration.

THE TRACHEA

The trachea begins opposite the lower part of the sixth cervical vertebra and bifurcates in front of the disc between the fourth and fifth thoracic vertebrae. Plates XXVIII, XXIX, XXXII and XXXIII show the first part of the trachea to the left of the midline, while Plate III shows it

apparently to the right of the midplane. The measurements were made to the right and left of a line through the center of the centrum of the vertebra and the middle of the interspace between the hyoid muscles. From Plates I, II, and III it is evident that the neck is rotated to the right, hence the deviation from the midplane. Over the second thoracic vertebra the trachea is divided symmetrically by the median line, but deviates to the right in the region of the arch of the aorta (Plate VII). It rests upon the oesophagus posteriorly and to the left. It is in relation anteriorly, above the sternum, with the isthmus of the thyreoid gland and sternothyreoid muscles. Below the upper border of the sternum the trachea is crossed by the left innominate vein, which receives near the midline the inferior thyreoid veins. At about this same level the innominate artery is in contact with the right anterior part of the trachea separating it from the junction of the innominate veins. The ascending aorta and vena cava superior separate the remainder of the trachea from the sternum. In the region of the seventh cervical and the first thoracic vertebrae, the trachea is covered laterally by the lateral lobes of the thyreoid. At the lower extremity of the thyreoid the trachea comes into relation laterally with the common carotid arteries. The left carotid runs nearly parallel with the trachea down to the arch of the aorta, the right one down to the innominate artery. The lower half of the trachea is in contact laterally with the superior lobe of the right lung but is separated from the left lung by the oesophagus, common carotid and subclavian arteries above and the arch of the aorta below. In the upper part of the mediastinum the vagi nerves are separated from the trachea by the carotid arteries. Below, the

left one is separated from the trachea by the aortic arch, while the right one lies between the trachea and the lung (Plates VI and VII). The right recurrent laryngeal nerve does not come into close relation with the trachea. The left recurrent lies in the left angle between the oesophagus and the trachea from the under part of the arch of the aorta to the larynx.

Mehnert[1] places the bifurcation of the trachea opposite the fifth or sixth thoracic vertebra and in old age as low as the seventh vertebra.

THE HEART

The heart is seen in section in Plates VIII to XII and in projection in Plates XXVIII, XXX, XXXI, XXXII, XXXIV and XXXV. The **base** lies between the second sternochondral articulations and the lower half of the fifth thoracic vertebra. The **apex** though poorly defined, may be located behind the fifth left costochondral articulation, about 7 cm. from the midline, at the level of the xiphosternal articulation and the lower border of the ninth thoracic vertebra. The **surface form** of the heart may be seen in Plate XXVIII. The base is represented by a line through the middle of the second sternochondral articulations. The right border lies entirely to the right of the sternum and extends from the lower part of the second right costal cartilage near the sternum, to the upper border of the fifth cartilage about 3 cm. from the midline. Its greatest distance to the right of the midline is at the lower end. The inferior border extends nearly in a straight line from the lower end of the right border to the apex point. It crosses the sternum from the lower part of the fifth right to the

[1] Loc. cit.

lower part of the sixth left sternochondral articulation. The left border extends upward, with a marked outward curve, from the apex point to the middle of the second left costal cartilage. Its greatest distance from the midline is about 9 cm. in the fourth intercostal space.

The outline as here mapped out is formed by all four chambers of the heart. The right auricle which is somewhat distended, forms the right half of the base, the entire right border and a small portion of the inferior border. The right ventricle forms the remainder of the inferior border, with the exception of a small strip near the apex which is formed by the left ventricle. It also forms the left half of the base and the upper portion of the left border, where the conus arteriosus rises above the left auricle. The left ventricle forms the small part of the inferior border about the apex and the lower two-thirds of the left border. The left auricle forms the short strip between the left ventricle and the conus arteriosus (Plate XXXII).

When viewed from the left side (Plates XXXI and XXXV) the main part of the heart is formed by the left ventricle with the left auricle above and behind it. The right ventricle forms the anterior boundary of the heart and separates the left ventricle from the sternum. The upper half of the posterior boundary is formed by the left auricle while the lower half is formed by the right auricle, with a small part of the left ventricle near the apex (Plates XI and XII).

When viewed from the right side (Plates XXX and XXXIV) the larger part is formed by the right auricle, with the right ventricle and its conus arteriosus forming the anterior boundary and the left auricle forming the upper half of the posterior boundary.

The positions of the orifices are indicated in Plates

XXVIII, XXX and XXXI. The **tricuspid** orifice is somewhat enlarged on account of the distention of the right auricle. It is oblong in outline, the long axis—superoinferior—being about 4.5 cm. and the short axis about 3.5 cm. in length. The long axis coincides roughly with that of the heart, and the plane of the orifice forms an angle of about 45 degrees with the midplane (Plates X and XI). The blood, in passing from the auricle into the ventricle, has a direction forward, to the left and a little downward. The orifice lies beneath the left half of the sternum extending from .5 cm. to the right of the midline, to the left border of the sternum. It extends from the level of the middle of the third to the upper part of the fifth sternochondral articulation or from the level of the upper border of the seventh to the lower border of the eighth thoracic vertebra.

The **pulmonary** orifice is behind the lower part of the second costal cartilage and the upper half of the second intercostal space at the left margin of the sternum. The plane of the orifice forms an angle of about 45 degrees with the coronal plane, so that the blood in passing into the pulmonary artery takes a direction upward, backward and a little to the left. The orifice is guarded by three semilunar valves, one of which is anterior, one internal and one posterior.

The **mitral** orifice is small and relatively wider than the tricuspid. Its long axis is nearly vertical, being about 4 cm. in length, while its short axis is about 3.5 cm. in length The blood takes a direction downward, forward and to the left in passing from the auricle into the ventricle. This orifice is located almost entirely to the left of the sternum behind the third costal cartilage, third intercostal space, and upper half of the fourth costal cartilage at the level of

the seventh thoracic vertebra. Its center is about 1.5 cm. above, 3.5 cm. behind and 2 cm. to the left of the center of the tricuspid orifice.

The aortic orifice lies behind the left half of the sternum at the level of the upper border of the third costal cartilage and opposite the middle of the sixth thoracic vertebra. The plane of this orifice is more nearly horizontal than that of any of the other openings. It is about 2 cm. below and 2 cm. internal to the pulmonary orifice. The blood in passing into the aorta takes a direction upward, to the right and a little backward. The semilunar valves which guard the opening are one anterior and two posterior. The mesial posterior cusp is a little more anteriorly placed than the lateral (Plate IX).

The heart enters into relations with the surrounding organs through the pericardium which surrounds it and which will be considered as a part of the heart in this paragraph. The right auricle is separated from the anterior thoracic wall by the thin anterior part of the right lung. The right ventricle is in contact for the most part with the gladiolus throughout the entire extent of that bone, and with the second, third, fourth and fifth left costal cartilages and the intercostal muscles. Nearly half of the narrow strip of the left ventricle seen in the anterior projection is in direct contact with the ribs and intercostal muscles. The remainder of the ventricle together with the left auricle, is covered anteriorly by the anterior part of the left lung. Thus the greater part of the anterior surface of the heart is not covered by the lungs. This uncovered area which is about 10 cm. wide across at the fourth ribs is to be explained by the extreme contraction of the lungs and accompanying distention of the right auricle (Plates X and XI) and by the exclusion of the left lung

from that part of the pleural cavity lying between the heart and the anterior thoracic wall by the adhesions of the mediastinal and costal pleurae.

Laterally the heart is in immediate contact with the anterior part of the internal surface of each lung. The right side of the heart may be divided into three areas each of which runs from above downward and forward and corresponds to one of the three lobes of the right lung. The upper area includes roughly the right auricula, and the conus arteriosus and is in relation with the superior lobe of the lung. The middle area includes the remainder of the right ventricle and the right auricle except the posteroinferior part near the opening of the vena cava inferior. It corresponds to the middle lobe of the lung. The lower area, which corresponds to the inferior lobe of the lung is small and includes a part of each auricle (Plates X, XI and XII).

The left surface of the heart may be divided in the same way into two areas, which correspond to the two lobes of the left lung. The upper area is the larger and includes the right ventricle, most of the left ventricle, and the superior and anterior part of the left auricle. This area corresponds very closely to the upper and middle areas of the right side. The lower area is a continuation outward of that part of the posterior surface of the heart in relation with the inferior lobe of the left lung. It includes the greater part of the left auricle and the posteroinferior part of the left ventricle.

The base of the heart is in relation with the great vessels which arise from it and with the large mediastinal lymph glands seen in Plate VII.

The heart is in relation, posteriorly, near the base, with the roots of the lungs. Below the roots of the lungs

it is in contact with the oesophagus and descending aorta. A small part of the internal surface of each lung reaches the heart external to the oesophagus and aorta (Plates VIII and IX). Below the disc between the seventh and eighth thoracic vertebrae, the aorta is separated from the heart by the left half of the oesophagus. From above downward, more and more of the posterior surface of the heart is covered by the inferior lobe of the left lung.

Inferiorly, the right auricle and internal part of the right ventricle rest upon the central tendon of the diaphragm, while the remainder of the right ventricle and the left ventricle rest upon the internal muscular portion of the left dome. These portions of the heart are in relation through the diaphragm with the left lobe of the liver. They lie on a line which runs outward, forward and slightly downward from the disc between the eighth and ninth vertebrae to the anterior extremity of the left fifth rib. From Plates XXVIII and XXXII it appears that the heart is in relation with the fundus of the stomach, but Plate XIII shows that the lower part of the pericardial cavity is separated from the stomach by the left lobe of the liver. The apparent intimate relation between the apex of the heart and the upper pole of the spleen is of the same nature (Plates XIII, XXXI and XXXV).

The position and relations of the heart in this cadaver differ somewhat from those given in many topographic anatomies. Cunningham[1] gives photographs of formalin hardened bodies, with the heart exposed, which show the heart to be about 2 cm. lower on the anterior wall, than in these projections. Quain[2] gives practically the same posi-

[1] Loc. cit.

[2] Thane, G. D., Quain's Elements of anatomy. Angeiology, II. ii. London, 1896.

tion as Cunningham. Joessel[3] gives the same position for the heart but differs as to the location of the orifices. He places the tricuspid, pulmonary and aortic orifices lower than they, but the mitral as high or higher than found in this case. Hermann and Ruedel[4] project the heart at a higher level upon the ribs of the anterior wall of the thorax, but in their table of levels place it lower upon the vertebral column than found here. The valves are lower and the planes of the tricuspid and mitral are more oblique in their subject. Henke[5] and Toldt[6] also place the heart at a lower level. Deaver[7] and Merkel[8] locate it at nearly the same level as found here, but place the orifices differently. Deaver finds them lower and Merkel higher than here. Both however place the tricuspid orifice in a more oblique position with more of it to the right of the midplane than shown in Plate XXVIII. The heart in this subject is more horizontally placed with its valves more vertical than in any of the cases referred to above. The arch of the aorta is also higher than is given in any of the above works. The fact that the apex of the heart seems to be high would lead one to think that the apical portion has been raised, thus making the inferior border nearly horizontal and rotating the valve areas into a more vertical direction. The lower part of the margin of the tricuspid

[3] Joessel, G., Lehrbuch der topographisch-chirurgischen anatomie. Bonn, 1899.

[4] Loc. cit.

[5] Henke, W., Construction der lage des herzens in der leiche. Tübingen, 1883.

[6] Toldt, C., Anatomischer atlas. 2 Aufl. Berlin und Wien, 1900.

[7] Deaver, J. B., Surgical anatomy. Philadelphia, 1899-1903.

[8] Merkel. F., Handbuch der topographischen anatomie. Braunschweig, 1885-1899.

orifice may have been pushed to the left by the distention of the lower part of the right auricle (Plates X and XI). In this connection it will be noted that the left dome of the diaphragm is at nearly the same height as the right one. It is possible that the adhesions of the left lung to the pericardium and diaphragm, the moderate distention of the stomach and the intraperitonaeal injection may have raised the left dome of the diaphragm and carried the apical portion of the heart upward to a position higher than it originally occupied. However, it is not probable that these factors will account for the base of the heart and the arch of aorta being higher than usual.

AORTA AND VENAE CAVAE

The aorta lies entirely to the left of the midplane at its origin from the left ventricle behind the third left sternochondral articulation. The **ascending aorta** inclines to the right as it goes upward so that the base of the innominate artery is to the right of the midplane behind the first sternochondral articulation. The aortic arch lies behind the left half of the manubrium at the level of the disc between the third and fourth thoracic vertebrae, and the upper half of the fourth vertebra. Its highest point is less than 1 cm. below the upper border of the sternum. The artery reaches the left side of the vertebral column at the level of the fifth vertebra and remains in close relation with the left anterior aspect of the vertebral column down to the point of bifurcation over the disc between the third and fourth lumbar vertebrae (Plates VIII to XIX and XXVIII, XXIX, XXXI, XXXII, XXXIII and XXXV).

At its origin the aorta is in contact with the conus arteriosus anteriorly, with the left auricula and auricle to the left and posteriorly, and with the right auricle to the

right (Plate IX). A little higher up, at the level of the fifth vertebra (Plate VIII), the left auricula has been replaced by the pulmonary artery, the left auricle by the right branch of the pulmonary artery, and the right auricle by the right auricula and vena cava superior. The remainder of the ascending aorta and the aortic arch are separated from the sternum and the left lung by large mediastinal lymph glands. The vena cava lies to the right of the ascending limb of the arch and is separated from it by the pericardium only (Plate VIII). The arch of the aorta is fitted closely around the left side of the trachea. The descending aorta is between the trachea and oesophagus internally and the internal surface of the left lung externally. The left bronchus passes under the arch of the aorta in contact with its concave surface and separates the descending limb from the pulmonary artery and the upper part of the left auricle. At the level of the fifth thoracic vertebra the oesophagus lies to the right of the aorta. It becomes gradually anterior to the aorta and crosses the artery in front of the ninth vertebra to reach the cardia of the stomach. The aorta makes a slight groove in the left lung posterior to the hilus but does not make an impression upon the lung near the base. The crura of the diaphragm cover the artery from the upper part of the tenth thoracic to the middle of the first lumbar vertebra, where the aorta pierces the diaphragm and comes into relation with the posterior surface of the pancreas. Just below the inferior border of the pancreas the artery is crossed by the left renal vein. At the level of the second lumbar vertebra the aorta passes behind the transverse portion of the duodenum. Below the duodenum the radix of the mesentery is attached to the posterior body wall over the aorta. From the arch to the disc between the first and second

lumbar vertebrae, the thoracic duct lies along the right side of the aorta. The two vessels pierce the diaphragm together. The cisterna chyli lies to the left of the aorta over the second lumbar vertebra. The thoracic duct lies between the aorta and the vena azygos major. The aorta and vena cava inferior are separated near the heart by the oesophagus. After the oesophagus enters the stomach the vessels are separated by the right crus of the diaphragm, down to the aortic opening of the diaphragm. The last 5 cm. of the aorta are in direct relation with the left side of the vein. The left vagus nerve lies upon the anteroexternal part of the aorta down to the diaphragm. Its recurrent laryngeal branch passes between the bronchus and the under surface of the arch on its way back to the larynx.

The **vena cava superior** is formed behind the right border of the manubrium at the level of the first sternochondral articulation. It descends nearly vertically downward to empty into the right auricle at the level of the second intercostal space and the lower part of the fifth thoracic vertebra. It lies between the ascending aorta and the anterior part of the internal surface of the right lung. It is separated from the sternum by the lung, and passes behind the right auricula just before entering the heart. Behind the upper part of the vena cava superior is the trachea and behind the lower part, the right branch of the pulmonary artery. The right phrenic nerve runs between it and the pleura.

The **vena cava inferior** is formed in front of the lower part of the fourth lumbar vertebra a little to the right of the midplane and empties into the posteroinferior part of the right auricle (Plate XII) at the level of the disc between the eighth and ninth thoracic vertebrae. The opening, into the heart, of the vena cava inferior is vertically under that

of the vena cava superior, and is also somewhat larger. At its origin the vein rests upon the anterior surface of the vertebral column and the right psoas major muscle. Over the second and first lumbar vertebrae, the right crus separates it from the vertebral column. From this level up to where it pierces the diaphragm it is separated from the centra by the lumbar portion of the diaphragm. It is crossed anteriorly by the third portion of the duodenum and the head of the pancreas and lies just internal to the first and second portions of the duodenum, and anterointernal to the right kidney, from which it is separated by the suprarenal gland. Above the level of these structures it is embedded in the posterior surface of the liver between the right and Spigelian lobes.

THE OESOPHAGUS

The oesophagus begins at the lower part of the sixth cervical vertebra and ends opposite the upper half of the tenth thoracic vertebra. It lies just anterior to the vertebral column near the midplane of the body. In the region of the last cervical and the first three thoracic vertebrae more than half of the oesophagus is to the left of the midplane. Over the fourth and fifth vertebrae it is pushed to the right of the midplane by the arch of the aorta. In the remainder of its course it deviates to the left and crosses the anterior surface of the aorta in front of the ninth vertebra. It pierces the diaphragm at this level and enters the cardiac portion of the stomach to the left of the tenth vertebra. Above the root of the lung it lies between the trachea and the vertebral column, with both of which it is in contact. It is in relation by its lateral surfaces above with the lateral lobes of the thyreoid gland

and below with the posterior part of the internal surface of each lung. The arch of the aorta separates it from the left lung at the level of the fourth vertebra. At the level of the fifth thoracic vertebra it is separated from the pulmonary artery by the bronchi and large bronchial lymph glands. At this same level the aorta lies to its left, the centrum of the vertebra behind it, and the vena azygos major to its right. Below this level it is separated from the vertebral column by the vena azygos major, the thoracic duct and the aorta, and is in contact anteriorly with the posterior surface of the heart down to the diaphragm. Below this it is in contact with the tuber omentale of the left lobe of the liver. It is in contact with the lung on either side in the region where it is anterior to the aorta and vena azygos major. The thoracic duct lies behind the oesophagus below the fourth thoracic vertebra, but crosses its left side and lies anteroexternal to it above the second thoracic vertebra.

STOMACH

The stomach lies in the left hypochondriac and epigastric regions. The fundus lies behind the left costal arch, and, in the midclavicular line, rises to the fifth rib on a level with the sixth sternochondral articulation. The **cardiac orifice** lies in the midaxillary plane about 2 cm. to the left of the midplane at the side of the upper half of the tenth thoracic vertebra, behind the sixth and seventh left costal cartilages near their junction with the sternum. The **pyloric orifice** is about 4 cm. to the right of the midplane at the level of the first lumbar vertebra. It is about 5 cm. in front of, 6 cm. to the right of, and 7 cm. below the cardiac orifice. The **lesser curvature,** which is a direct con-

tinuation of the right side of the oesophagus, lies to the left of the midplane at the eleventh vertebra and to the right at the twelfth vertebra. It is under cover of the inferior surface of the liver. The **greater curvature** of the stomach, which is a continuation of the left side of the oesophagus, passes upward and outward from the cardia under the fifth rib below the left dome of the diaphragm. It comes downward under the seventh rib, leaves the costal arch under the tenth costal cartilage, crosses the midplane at the upper part of the first lumbar vertebra and ends at the outer part of the pylorus just internal to the end of the right ninth cartilage. It lies in direct contact with the diaphragm and the anterior abdominal wall through the greater part of its course.

The **anterior surface** of the fundus and the body are in contact with the inferior surface of the left lobe of the liver, the diaphragm and anterior abdominal wall. The anterior border of the left lobe of the liver is relatively high so that the stomach comes into direct contact below the liver with the anterior abdominal wall internal to the costal arch and with the diaphragm external to the costal arch. That part of the anterior surface of the pyloric portion lying to the left of the midplane is in contact with the internal part of the inferior surface of the left lobe, but that part lying to the right of the midplane is in contact with the inferior surface of the quadrate lobe and the peritonaeal surface of the fundus of the gall bladder (Plates XVI and XVII).

The **posterior surface** of the stomach is in contact with the spleen which separates it from the diaphragm and base of the lungs below the level of the tenth thoracic vertebra. (See relations of lung to stomach.) The internal part of the posterior surface of the stomach is attached to the

diaphragm above the disc between the eleventh and twelfth vertebrae, but below this level they are separated by the lienal recess of the lesser peritonaeal cavity. This peritonaeal portion of the posterior surface of the stomach is in relation with the pancreas, suprarenal gland, kidney and spleen. The superior border of the pancreas crosses the lower part of the stomach and separates it from a part of the suprarenal gland, kidney and spleen. (Plates XVI, XXVIII and XXXII.) Its anterior surface lies immediately below this part of the stomach. The upper half of the suprarenal gland, lies between the stomach and the vertebral column and the medial border of the kidney. Posteroexternal to the suprarenal area, also above the upper boundary of the pancreas, the upper pole of the kidney is in contact with the stomach. This area is bounded inferiorly by the pancreas, internally by the suprarenal gland, superiorly by the upper limit of the kidney between the suprarenal gland and the spleen, and externally by the spleen (Plates XXVIII and XXXII).

The **pyloric portion** of the stomach is in relation posteriorly with the neck and head of the pancreas, the hepatoduodenal ligament and the first portion of the duodenum. The greater curvature is bound closely to the transverse colon by the great omentum.

Cunningham, Addison[1] and Ruedinger,[2] place the cardiac orifice higher than found in this subject. Merkel places it at the level of the eleventh thoracic vertebra, which is several centimeters lower than most anatomists locate it. The difference seems to be more in its relation to the verte-

[1] Addison, C., On the topographical anatomy of the abdominal viscera in man. Journal of anat. & physiol., XXXIII, XXXIV and XXXV.

[2] Rüdinger, A., Cursus der topographischen anatomie. München, 1899.

bral column than to the anterior wall, since nearly every anatomist locates it near the seventh left sternochondral articulation. The pylorus in this subject is lower and further from the midplane than the above mentioned anatomists place it, but when it is remembered that the pylorus moves downward and to the right as the stomach is filled and that the stomach was moderately distended in this case, it will appear that the position of the pylorus as shown in these plates agrees more or less closely with the usual condition.

DUODENUM AND JEJUNOILEUM

The duodenum is seen in Plates XVII and XVIII. It begins at the pylorus opposite the first lumbar vertebra, rises about 1 cm. and turns backward and downward and runs by the side of the vertebral column as far as the disc between the second and third vertebrae. In its course upward and to the left it crosses the vertebral column opposite the lower half of the second and the upper half of the third lumbar vertebrae and ends about 5 cm. to the left of the midline opposite the first lumbar vertebra. The organ when viewed from the front (Plates XXVIII and XXXII) is roughly U-shaped with the right limb of the U nearly vertical, the two ends at about the same level and about 10 cm. apart. The lowest point of the U is in front of and a little to the right of the middle of the third lumbar vertebra.

The **first portion** lies between the liver externally, the head of the pancreas internally, the pylorus anteriorly and the kidney, suprarenal gland and vena cava inferior posteriorly. (Plate XVII). Above it, is the inferior surface of the right lobe of the liver, to which it is bound by the hepatodu-

odenal ligament, containing the root structures of the liver. The **second portion** is bound to the inner part of the anterior surface of the right kidney as far down as the lower margin of the hilus. For a very short space below the hilus the duodenum is internal to the kidney and rests upon the psoas major muscle and the ureter. Internally this second portion is attached to the vena cava inferior behind and the head of the pancreas in front. Anteriorly it is in relation to the antrum pyloricum and the beginning of the transverse colon. Externally it is in contact with the inferior surface of the liver above, and is attached to the hepatic flexure below (Plates XVII and XVIII). The third or **transverse portion** lies upon the vena cava inferior and aorta in front of the second and third vertebrae, and behind the lower part of the head of the pancreas which projects downward into the base of the mesentery attached to this part of the duodenum. The anterior surface of this transverse portion is crossed by the mesenteric vessels, and the large lymph glands which accompany them. The **fourth portion** of the duodenum is bound to the aorta, receptaculum chyli and left renal vessels posteriorly, and has the radix of the mesentery attached to it anteriorly. The head and neck of the pancreas are attached to the internal surface while the body of the pancreas passes outward above and behind the duodenojejunal angle. The lateral and anterior surfaces of this portion are in relation with coils of the jejunoileum.

The duodenum in this case corresponds closely with Schiefferdecker's[1] second position of the duodenum. However in the case of his figure as in the location given by

[1] Schiefferdecker, P., Beiträge zur topographie des darmes. Archiv für anatomie und entwickelungsgeschichte. 1886. Plate XVI, fig. 2.

most anatomists the duodenojejunal angle is at the level of the second instead of the first lumbar vertebra. Jonnesco[2] places the transverse portion across the fourth or fifth lumbar vertebra and the pylorus and duodenojejunal angle at the side of the first lumbar vertebra.

The **jejunoileum** begins at the duodenojejunal angle about 5 cm. to the left of the midplane at the level of the first lumbar vertebra, and ends at the ileocolic valve about 3 cm. to the right of the midplane over the right end of the disc between the fourth and fifth lumbar vertebrae. The coils of this part of the intestine are so variable in position and relations that they are not represented in the projections. The mesentery is attached to the posterior body wall along a line nearly straight from the duodenojejunal angle to the ileocolic valve. In the upper half this attachment is to the front of the fourth portion of the duodenum. In the lower half it is at first attached to the aorta, then to the vena cava inferior and right common iliac vessels.

THE LARGE INTESTINE

The **caecum** lies in the right iliac fossa and extends as far down as the promontory of the sacrum. Its **apex** is about 4 cm. below the ileocolic valve. The latter is anterior and to the right of the disc between the fourth and fifth lumbar vertebrae, about 1 cm. below a line connecting the highest points of the crests of the ilia and 3 or 4 cm. above a line connecting the anterior superior iliac spines.

The **vermiform appendix** arises from the posterior part of the internal surface of the caecum about midway between the ileocolic valve and the apex of the caecum, and extends

[2]Jonnesco, T., Poirier, P. et Charpy, A., Traité d'anatomie humaine, IV.

inward anterior to the right half of the fifth vertebra. It lies internal to the caecum and is connected to the intestine by a short mesoappendix. The appendix is about 9 cm. in length, .5 cm. in diameter, and with a lumen about .2 cm. in diameter. When seen from the front the first 7 cm. of the appendix form an irregular W-shaped figure, with the last 2 cm. lying between the W and the vertebral column (Plates XXVIII and XXXII). The caecum is almost entirely covered with peritonaeum, the upper part being slightly adherent to the psoas muscle posteriorly (Plate XXI). It lies in the lateral angle of the body cavity between the iliopsoas and transversus abdominus muscles. Internal to it are coils of the jejunoileum, and the appendix.

The **ascending colon** is considerably distended in its lower three-fourths, and fills a large part of the right lumbar region of the abdominal cavity. It ascends nearly vertically upward from the caecum to the inferior surface of the liver. It is covered with peritonaeum in front and on the two sides except where it comes into contact internally, near the hepatic flexure, with the duodenum (Plate XVIII). The lower half is in relation internally with the jejunoileum, anteriorly and externally with the body wall. Posteriorly it is attached to the quadratus and psoas muscles. The upper half is adherent internally to the second portion of the duodenum and posteriorly to the lower half of the kidney. Externally it is in contact with the liver and anteriorly with the beginning of the transverse colon. The ureter runs downward internal to the colon but does not enter into close relation with it as Plates XXVIII and XXXII might lead one to believe.

The **hepatic flexure** is at the level of the second lumbar vertebra about 7 cm. to the right of the midplane and 4 cm. in front of the midaxillary plane. Upon the anterior wall

it may be located a little internal to the right tenth costal cartilage. It is anterior and external to the hilus of the kidney. It lies between the right lobe of the liver externally and the descending duodenum internally. The right lobe of the liver lies above the flexure while the fundus of the gall bladder is about 1 cm. above and in front of its highest point.

Quain[1] locates the hepatic flexure at the level of the first lumbar while Hermann and Ruedel[2] locate it as low as the upper part of the third lumbar vertebra.

The **transverse colon** is also distended near its beginning but the part lying to the left of the midline is contracted. At the hepatic flexure the colon turns forward, downward and to the left. The downward turn is small so that the colon soon takes a direction upward, backward and to the left (Plates XXVIII and XXXII) to reach the inferior pole of the spleen. The highest point reached by the colon is at the level of the upper border of the twelfth thoracic vertebra about 5 cm. to the left of the midplane and about 5 cm. in front of the midaxillary plane. From this highest point the colon descends rapidly, crosses the midaxillary plane at the level of the first lumbar vertebra and comes into contact with the lower end of the spleen (Plates XVI, XXVIII, XXIX, XXXI, XXXII, XXXIII and XXXV). This part of the colon is peritonaeal and is attached to the body wall by a mesocolon which arises from the anterior surface of the second portion of the duodenum and the head and anterior border of the pancreas. It is bound more or less closely to the greater curvature of the

[1] Thane, G. D. and Godlee, R. J., Quain's elements of anatomy. Appendix. Superficial and surgical anatomy. London, 1896.

[2] Loc. cit.

stomach by the great omentum. At the beginning it is in relation anteriorly with the anterior abdominal wall, externally and superiorly with the inferior surface of the right lobe of the liver, and posteriorly with the ascending colon, second portion of the duodenum and the head of the pancreas. A little higher up it is separated from the duodenum by the antrum pyloricum. The part of the colon lying to the left of the midplane is in relation with the body of the pancreas posteriorly, from the upper part of which it is separated by the greater curvature of the stomach. It arches over and is in contact with the duodenojejunal angle. At the level of the first lumbar vertebra it comes into contact with the inferior portion of the gastric surface of the spleen, and becomes retroperitonaeal.

The **splenic flexure** is in the midaxillary plane at the level of the first lumbar vertebra. It is separated from the ninth intercostal space by the diaphragm only, and from the kidney by the lower part of the tail of the pancreas.

The **descending colon** is more contracted than the other portions of the large intestine and extends from the splenic flexure to the crest of the ilium. It lies a little posterior to the midaxillary plane, and runs downward, inward and forward between the kidney and the lateral body wall above and the psoas and quadratus muscles and the body wall below. It is covered with peritonaeum on its anterior surface and a part of each lateral surface. Below the spleen and pancreas the colon lies upon the external (anterior) surface of the kidney (Plate XVIII). In the lower part of its course it lies in the groove between the psoas and quadratus muscles. Its peritonaeal surface is in contact with coils of the jejunoileum.

The **sigmoid colon** lies in the left iliac fossa and in the true pelvic cavity. It continues downward in the same

direction as the descending colon from the iliac crest to the level of the first sacral vertebra where it turns horizontally inward and backward to pass over the brim of the pelvis (Plates XXVIII, XXIX, XXXII and XXXIII). The **pelvic portion** of the sigmoid is coiled upon itself and lies upon the anterior surface of the rectum in the region of the first four sacral vertebrae. The **iliac portion** of the sigmoid is contracted but soon after crossing the brim of the pelvis the colon becomes dilated. It turns downward for a short distance, separated from the anterior wall by the jejunoileum and its mesentery. Opposite the fourth sacral vertebra the colon turns upon itself in the anteroposterior direction and passes upward between the descending loop and the first part of the rectum. At the level of the second sacral vertebra the intestine makes another turn in the anteroposterior direction and joins the rectum. Thus there are two loops of the sigmoid and the first part of the rectum in the same anteroposterior plane anterior to the middle portion of the sacrum. The iliac portion of the sigmoid rests upon the iliopsoas. Its mesocolon is very short. The pelvic portion has a longer mesocolon which allows it to swing free in the pelvic cavity where it is in contact anteriorly and laterally with the jejunoileum.

The **rectum,** the remainder of the large intestine may be divided into two parts nearly equal in length. The upper part is covered upon its anterior surface with peritonaeum and extends from near the base of the sacrum to about 1 cm. above the tip of the coccyx. The lower part lies below the peritonaeal cavity. The **first portion** is greatly dilated and nearly fills the true pelvic cavity. It is covered with peritonaeum on its anterior surface and a part of each lateral surface. The posterior surface is attached to the concave anterior surface of the

sacrum and coccyx by connective tissue containing nerves, blood vessels and lymph glands. On either side of the rectum are the large vessels and nerves which pass out through the great sacrosciatic notch (Plates XXII and XXIII). Anteriorly it is in relation above with the pelvic portion of the sigmoid colon and below with the bladder. The ureters and vasa deferentia pass across the lower part of the anterior surface to gain the posterior surface of the bladder (Plate XXIII). The lower half of the rectum is contracted. Its anterior wall is a vertical continuation of the anterior wall of the upper half. It is surrounded by the cone-shaped levator ani muscle with which its muscular coat becomes continuous near the anus (Plates XXIV and XXV). It is in contact above, anteriorly with the prostate gland and posteriorly wtih the tip of the coccyx. Its lower part is separated from the bulb of the urethra anteriorly by the perinaeal body. Its relation to the ischiorectal fossae posterolaterally is well shown in Plates XXIV and XXV.

THE LIVER

The liver is seen in section in Plates XII to XVIII and in projection in Plates XXVIII to XXXV. The greater part of it lies in the right hypochondriac region, but it crosses the epigastric into the left hypochondriac region. The **superior boundary of the surface outline** is nearly horizontal and crosses the sternum at the level of the fifth sternochondral articulations and the upper border of the ninth thoracic vertebra. In the midclavicular regions this boundary is in the fourth intercostal spaces only a few millimeters higher than at the midline. This slight difference is due to the fact that the left dome of the diaphragm is at nearly the same level as the right one. The **right boundary**

of the surface outline is slightly convex outward following the lateral part of the diaphragm and body wall down to the level of the middle of the third lumbar vertebra about .5 cm. below the lowest point of the tenth rib. The **inferior boundary** crosses the anterior abdominal wall from the tip of the right tenth to the left seventh costal cartilage about 1 cm. above the tip of the eighth cartilage, and ends behind the left sixth rib about 3 cm. external to the midclavicular line. It crosses the anterior midline about 7 cm. below the xiphosternal articulation or about one-third of the distance from this articulation to the umbilicus. The inferior boundary is formed by the anterior border and when seen from behind it crosses the vertebral column from the right end of the disc between the twelfth thoracic and first lumbar vertebrae to the left end of the next disc above. The greatest lateral extent of the liver is across the sixth sternochondral articulations and tenth vertebra, where the organ extends nearly 12 cm. to either side of the midline.

When seen from the right side (Plates XXX and XXXIV) the liver fills the upper half of the abdominal cavity. Its highest point is about 5 cm. and its lowest 1 cm. anterior to the midaxillary line. It is about 18 cm. in its superoinferior length.

Plates XXXI and XXXV represent the **left lobe** of the liver only. Since this lobe is very thin near its tip, but enlarges rapidly near the midplane of the body a double projection is given in order to show the relation of the liver to the body wall and to the other organs in the region. The large outline is from measurements at the junction of the right and left lobes, the diagonal crossing this outline represents the course of the anterior border of the liver from the tip of the left lobe to where it crosses the midline of the body.

The liver is separated by the diaphragm from the heart and lungs. The **superior surface of the right lobe** is almost entirely under cover of the base of the right lung. Near the midplane it is overlaid by that part of the right auricle into which the vena cava inferior opens. The **superior surface of the left lobe** lies under the heart and the base of the left lung. The anterointernal part of the surface is in relation with the heart. In the region of the inferior caval opening, in common with the right lobe, the left lobe is in relation with the right auricle. This area is small and lies to the right of the midplane of the body. The remainder of the cardiac area is roughly quadrilateral in form and is divisible into an anterointernal and a posteroexternal triangle. The anterior triangle corresponds to the right ventricle, the posterior to the left ventricle. Posterior and external to the cardiac area the liver is in relation with the base of the left lung (see relations of lung and heart). Below the lungs and heart the superior surface of the liver is in contact with the diaphragm and abdominal wall.

The **posterior surface of the right lobe** is attached to the diaphragm. It is in relation through the diaphragm with the inner and posterior part of the base of the right lung. The nonperitonaeal upper pole of the suprarenal gland is interposed between this surface of the liver and the diaphragm opposite the disc between the eleventh and twelfth thoracic vertebrae (Plate XV). The inner part of the posterior surface is separated from the base of the Spigelian lobe by a deep groove containing the vena cava inferior (Plates XIII, XIV and XV). The **posterior surface of the left lobe** is narrow and triangular with its apex outward towards the beginning of the left triangular ligament. It lies in section XII (not shown in the plates) over the

crura of the diaphragm which separates it from the oesophagus and aorta.

The **posterior surface of the Spigelian lobe** corresponds to the tenth, eleventh and upper half of the twelfth thoracic vertebrae. It is covered with peritonaeum and is separated by the right crus of the diaphragm from the base of the right lung and oesophagus above (Plate XIII) and from the vena azygos major, thoracic duct and aorta below (Plates XIV and XV).

The **inferior surface of the left lobe** is in contact with the anterior (superior) surface of the fundus, body and a small part of the pyloric portion of the stomach. The tuber omentale lies upon the cardia and crura of the diaphragm above and the lesser curvature and lesser omentum below (Plates XIII and XIV). This is the part of the liver in contact with the oesophagus from where the oesophagus passes through the diaphragm to where it enters the stomach.

That portion of the Spigelian lobe belonging to the inferior surface is separated from the tuber omentale of the left lobe of the liver and the anterior surface of the stomach by the lesser omentum. The left or free margin of the Spigelian lobe is in close relation with the lesser curvature of the stomach.

The right portion of the pars pylorica is in contact with the **quadrate lobe** and the gall bladder. In front of the lower part of the pyloric area of the quadrate lobe is a slight depression, continuous with a similar area on the right lobe in which the transverse colon is seen in Plates XVII and XVIII.

Anterior to the midaxillary plane the **inferior surface of the right lobe** is in relation with the root structures of the liver and the vena cava inferior in the upper part, the

duodenum in the middle part and the hepatic flexure, ascending, and transverse colons in the lower part (Plates XVII and XVIII). Posterior to the midaxillary plane the right lobe is fitted over the upper half of the anterior surface of the right kidney (Plates XVI, XVII and XVIII). The peritonaeal portion of the right suprarenal gland comes into contact with this surface of the liver between the upper part of the kidney and vena cava inferior (Plate XVI). This area is continuous with the suprarenal area on the posterior surface seen in Plate XV. The liver does not come into contact with the jejunoileum at any point.

The **gall bladder** lies along the right costal margin with its right half under cover of the eighth and ninth costal cartilages. It is only moderately distended so that it is entirely under cover of the liver anteriorly. It lies in a shallow groove between the right and quadrate lobes and is in contact internally with the pylorus and first part of the duodenum (Plates XVI and XVII). The fundus is about 1 cm. above and in front of the highest part of the hepatic flexure. The neck is prolonged upward and inward as the **cystic duct** into the hepatoduodenal ligament. This ligament connects the liver, above the neck of the gall bladder, with the superior duodenum, pancreas, and pylorus and contains the bile duct, hepatic artery, portal vein and lymph glands, in their usual relations to each other. The root structures of the liver are separated from the vena cava inferior by a small peritonaeal pocket, the beginning of the vestibule of the lesser peritonaeal cavity (Foramen epiploicum [Winslowi], Plate XVI).

The main differences in position and relations of the liver as seen in these plates and that usually described seems to be due to two conditions: First, the left lobe is compressed in the superoinferior direction and extends far over

into the left hypochondriac region; second, the left dome of the diaphragm is about as high as the right, permitting the left lobe of the liver to rise to the same level as the right lobe. The tip of the left lobe is from 2 to 5 cm. farther to the left of the midline than is figured in Toldt, Joessel, Hermann und Ruedel, Cunningham, and Quain. Deaver says that the left lobe rarely extends more than 5 cm. to the left of the sternum. The superior surface is more horizontal than shown in Merkel, Quain, Joessel, et al. The difference is due largely to the higher level of the upper border of the left lobe in this case. Joessel places the highest point of the left lobe nearly 2 cm. lower and much nearer the midplane than in this subject. The level of the upper border of the right lobe corresponds more closely to the locations given by the above anatomists than does that of the left lobe. Deaver places it at the lower border of the fifth rib in the mammary line, while Hermann and Ruedel place it at the upper margin of the fourth rib. However it is probable that this seemingly great difference is due to the differences in the relation of the sternum and ribs to the vertebral column in the two subjects. This is true with respect to the difference between Hermann and Ruedel's projections and those in this paper, since in both the upper boundary corresponds to the upper margin of the ninth thoracic vertebra. The only other difference to be noted is the obliquity of the anterior border. This is due to the left lobe being somewhat higher than usual and very thin in its superoinferior direction. This border as given by most anatomists crosses the anterior abdominal wall from the ninth right to the eighth left costal cartilage, or much more nearly horizontal than this one.

THE PANCREAS

The pancreas is seen in Plates XVI, XVII, XVIII, XXVIII and XXXII. The **head** lies anterior to the first two lumbar vertebrae. It fills the concavity of the duodenum, with its lower part lying upon the anterior surface of the transverse duodenum. The **body** of the gland extends outward from the upper and left part of the head to the lower part of the gastric surface of the spleen. It passes above and behind the duodenojejunal angle, between it and the hilus of the left kidney. The **tail** is the triangular pyramidal extremity of the gland, which turns upward from the outer end of the body into the space between the spleen, kidney and stomach.

The **head** is flat with its posterior surface bound tightly to the vena cava inferior and left renal vein above and the transverse duodenum below. The vena cava and renal vein separate it from the crura of the diaphragm. The anterior surface of the head is covered with peritonaeum and is in relation with the pylorus and the transverse colon. The right border of the head is attached to the left side of the descending duodenum and presents a groove in its upper half in which the common bile duct passes downward to open into the posterior part of the descending duodenum. The left border of the head is separated from the ascending duodenum by the superior mesenteric vessels. These vessels make a groove in the pancreas, which begins above near the posterior part of the left side and runs downward and forward across the left border to reach the base of the mesentery (Plates XVII and XVIII).

The **body** of the pancreas is prismatic in form. The **anterior surface** is peritonaeal, faces upward and forward and is in relation with the posterior surface of the stomach.

The **inferior surface** is also peritonaeal. It faces downward and a little forward and is in relation by its inner part with the duodenojejunal angle and by its outer part with coils of the jejunoileum. The **anterior border** which separates these two surfaces is very well marked in its outer two-thirds where it gives attachment to the transverse mesocolon.

The **posterior surface** is retroperitonaeal. It is in contact, near the midline of the body, with the coeliac axis and mesenteric vessels. The splenic vessels run across the posterior surface, in a shallow groove, from within outward and upward. The coeliac plexus and the semilunar ganglia surrounding these vessels separate the pancreas from the crura of the diaphragm in the region of the twelfth thoracic and first lumbar vertebrae (Plate XVI). The outer half of this surface rests upon the left suprarenal gland and kidney. The pancreas is in contact with the lower two-thirds of the suprarenal. Just external to the suprarenal the pancreas is bound to the kidney from about 2 cm. below the upper pole to the middle of the hilus. The outermost part of the posterior surface is in contact with the spleen. The part of the spleen in contact with the body of the pancreas is small and lies between the gastric and renal surfaces of the spleen, and below the splenic area in contact with the tail of the pancreas.

The **tail** of the pancreas is peritonaeal on its anterior surface only where it is in relation with the posterior surface of the stomach. Its inferior (external) surface is attached to the spleen, its posterior (internal) surface to the anteroexternal surface of the kidney. The splenic vessels run along its superior border and pass over its apex to reach the hilus of the spleen. The lowest portion of the tail, at

its junction with the body, is in close relation anteroexternally with the splenic flexure of the colon (Plates XVI, XVII, XXVIII and XXXII).

THE SPLEEN

The spleen appears in Plates XIII to XVI and XXVIII, XXIX, XXXI, XXXII, XXXIII and XXXV. It lies in the left hypochondriac region upon the diaphragm and posterior abdominal wall opposite the ninth, tenth and eleventh ribs. The **upper pole** is at the level of the lower border of the ninth thoracic vertebra, and the **lower pole** at the level of the lower border of the first lumbar vertebra. Upon the anterior body wall the upper pole is at the level of the lower border of the fifth rib in the midclavicular line, 8 cm. from the midline, and the lower pole in the eighth intercostal space, about 11 cm. from the midline. The organ is ovoid in outline. Its long axis is 11 cm. in length and a little more nearly vertical than the tenth rib, inclining from above downward, outward and forward.

The **external or diaphragmatic surface** is directed backward in the upper half and outward in the lower half, and is in contact with the diaphragm (Plates XIV, XV and XVI). The upper part of this surface is in relation with the posterior part of the base of the left lung (Plate XIII).

The **upper pole** is separated from the posterior and external part of the inferior surface of the left lobe of the liver by a portion of the fundus of the stomach. The upper pole and the greater part of the external and gastric surfaces are covered with peritonaeum. The **posterior (internal) border** is bound to the diaphragm. The **anterior (external) border** is free in its upper three-fourths, and adherent to the splenic flexure in its lower fourth.

The **internal surface** may be divided into four areas corresponding to the four organs in contact with the spleen anterointernally. The gastric area includes a little more than the upper half of the spleen and may be bounded below by a line drawn from the middle of the posterior border to the junction of the upper three-fourths with the lower fourth of the anterior border. The upper and inner part of this area of the spleen is adherent to the stomach (Plate XIV). The remainder of the gastric area is separated from the stomach by the lesser peritonaeal cavity internal to the hilus of the spleen and by the gastrosplenic omentum and greater peritonaeal cavity external to the hilus. The posterior part of the internal surface below the gastric area is in contact with the posterior part of the anterior (external) surface and external border of the kidney. The pancreatic area is a small triangular space between the lower part of the gastric area anterosuperiorly, the renal area posteriorly and the posterior border of the spleen near the inferior pole, inferiorly. The remainder of the internal surface of the spleen, including the inferior pole, is in contact with the splenic flexure of the colon.

Quain places the upper pole of the spleen at the level of the disc between the tenth and eleventh vertebrae, and the lower pole at the first lumbar vertebra. Deaver places the upper limit at the ninth and the lower limit at the eleventh thoracic spine. Both of these measurements give a very much shorter spleen than is seen in this subject.

THE KIDNEYS

The kidneys appear in Plates XVI, XVII, XVIII, and XXVIII to XXXV. The two organs present many points in common but differ sufficiently in the details of their

topography to require a separate discussion of each.

The **right kidney** is of a long oval shape with its two margins of nearly the same curvature. It lies upon the posterior body wall in the right lumbar region, and extends from the level of the middle of the twelfth thoracic to the middle of the third lumbar vertebra. Its long axis extends from below upward, backward and inward. and if prolonged upwards it would cross the midplane behind the middle of the tenth thoracic vertebra. The **upper pole** is about 3.5 cm. from the midplane and 2.5 cm. behind the midaxillary plane while the **lower pole** is about 9 cm. from the midline in the midaxillary plane. The superoexternal half of the **posterior surface** lies over the eleventh intercostal space, and twelfth rib (Plates XXIX and XXXIII). The lower half of the organ lies below and internal to the twelfth rib. The kidney is separated from the vertebral column above the second lumbar vertebra by the diaphragm, and below this level by the psoas major.

The **anterior surface** of the right kidney is peritonaeal for the most part, and in relation with the posterior part of the inferior surface of the liver. When seen from the front the kidney is nearly covered by the eighth, ninth and tenth right costal cartilages (Plates XXVIII and XXXII). The lower half of the suprarenal fits over the upper part of the medial border and separates the kidney from the vena cava inferior (Plate XVI). The duodenum is bound to the medial border and anterior surface from the suprarenal down to the lower part of the hilus. From the hilus to the lower pole, external to the duodenum, the hepatic flexure and ascending colon cover the internal part of the anterior surface of the kidney. The **hilus** is opposite the second lumbar vertebra.

The left **kidney** is shorter, broader and thicker than

the right. Its outer border is much more convex than its inner. The organ is located on the posterior abdominal wall in the left lumbar region extending from the disc between the eleventh and twelfth thoracic vertebrae to the disc between the second and third lumbar vertebrae. It is less inclined than the right kidney, in both the frontal and the sagittal plane. If its long axis were prolonged upward it would cross the midplane in the region of the sixth thoracic vertebra. The **upper pole** is about 4 cm. from the midplane while the lower pole is only about 7 cm. from it. The entire organ lies behind the midaxillary plane (Plates XXXI and XXXV), and at a slightly higher level than the right kidney (Plates XVI, XVII, XVIII and XXVIII to XXXV). Posteriorly it lies over the eleventh rib, eleventh intercostal space and the twelfth rib. It does not extend below the tip of the twelfth rib more than about 1 cm., while the right kidney extends nearly 4 cm. below the tip of the right twelfth rib. When seen from the front more than one-half of the left kidney is under cover of the costal arch extending as far outward as the seventh costochondral articulation. The **posterior surface** rests upon the diaphragm above and the psoas and quadratus muscles below.

The body of the pancreas crosses the **anterior surface** of the kidney in the region of the hilus dividing it into three areas. Above the pancreas the kidney is in relation with the suprarenal, stomach and spleen, and below the pancreas, with the colon and jejunoileum. The suprarenal fits over the upper pole and medial border down to the hilus. The lower part of the suprarenal separates a portion of the kidney from the pancreas (Plate XVI). The posterior part of this upper area and the lateral border are attached to the spleen. The remainder of this upper area is in relation with the stomach. It is small and bounded

below by pancreas, in front by suprarenal, above by the upper pole of the kidney from the suprarenal to the splenic area, and externally by the spleen above and the tail of the pancreas below, (Plates XVI, XXVIII and XXXII). This gastric area is the only peritonaeal area of the left kidney above the lower border of the pancreas. Below the pancreas the external part of the anterior surface is bound to the descending colon. The internal part of this surface is covered with peritonaeum and is in relation with coils of the jejunoileum.

The hilus of the left kidney is also a little higher than that of the right. It is opposite the lower half of the first lumbar and the first lumbar intervertebral disc.

The upper poles of the kidneys are here from a half to an entire vertebra lower than the positions given by Thane and Godlee, Merkel and Deaver. The lower poles correspond more closely to their descriptions.

THE URETERS AND THE BLADDER

The ureters lie upon the psoas major muscles in the abdominal cavity and the obturator internus muscles in the pelvic cavity. At first each ureter is external to the psoas minor and its tendon, but crosses the tendon at the fourth lumbar vertebra. Near the brim of the pelvis each ureter comes into close relation with the anterior surface of the common iliac vein (Plate XXI). The ureters pass down the lateral pelvic walls in company with the internal iliac veins and their superior vesical branches (Plates XXII and XXIII). At the hilus of the kidney each ureter lies behind the renal vessels. From the renal vessels down to the brim of the pelvis the ureters lie behind the peritonaeum of the posterior abdominal wall and are in relation with coils of

the jejunoileum. In the pelvic cavity they lie, at first, by the side of the rectum, but lower down pass across its anterior surface to reach the posterior surface of the bladder. In going from kidney to bladder each ureter inclines inward and forward (Plates XXVIII to XXXV).

The bladder was empty in this subject. It lies entirely within section XXIII, between the heads of the recti muscles and the upper half of pubic arch anteriorly and the rectum in the region of the coccyx posteriorly.

THE SUPRARENAL GLANDS

The right suprarenal gland extends from the lower part of the eleventh thoracic vertebra to the lower part of the first lumbar vertebra. It lies along the upper half of the medial border of the right kidney and extends above the kidney into the space between the posterior surface of the liver and the diaphragm (Plate XV). It is in contact posterointernally with the diaphragm and anterointernally with the vena cava inferior. The upper half is nonperitonaeal, the lower half is covered with peritonaeum on its anterior surface and is in contact with the inferior surface of the liver. The inferior pole lies posterior to the first part of the duodenum (Plate XVII).

The left suprarenal is shorter and broader than the right one. The upper pole is about .7 cm. lower than that of the right. It covers the medial border of the left kidney from the upper pole to the hilus. Its posterior (internal) surface lies upon the diaphragm. Its anterior (external) surface is covered with peritonaeum above the superior border of the pancreas, where it is in contact with the posterior surface of the stomach. The remainder of the anterior surface is in contact with the posterior surface of the pancreas. The lower pole lies just above the left renal vessels.

These suprarenal glands differ in their topography from what is given by topographic anatomists in about the same way as do the kidneys since the two organs are so intimately connected. They do not have the characteristic Y-shape in the projections because only the widest part of the outline was measured in each plane.

THE THYREOID GLAND

The thyreoid gland, while not belonging to the thoracic and abdominal viscera, was included in the projections in order to show its relation to the lungs, trachea, oesophagus, heart and great vessels.

The **left lateral lobe** of the thyreoid is the larger and extends from the middle of the ala of the thyreoid cartilage to the fifth ring of the trachea, or from the lower border of the fifth cervical to the middle of the second thoracic vertebra. It is in relation internally with the larynx and pharynx above, and with the trachea below; posterointernally with the longus colli above and the oesophagus below; posteroexternally with the common carotid artery and internal jugular vein; and anteroexternally with the sternothyreoid muscle, and near the apex with the omohyoid muscle.

The **right lateral lobe** is shorter and broader than the left. Its relation is about the same as that of the left lobe except that being the broader it projects backward over the side of the oesophagus more than the left one (Plate III).

The superior thyreoid vessels and recurrent laryngeal nerves are to be seen in Plates III and IV, between the surface of each lobe and the oesophagus. The lower part of each lobe is separated from the apex of the corresponding lung by the vessels and nerves of the region.

The lateral lobes are connected to each other in their lower halves by the **isthmus,** which lies upon the anterior surface of the trachea over the second, third and fourth tracheal rings. It is difficult to distinguish the lines of separation between the lateral lobes and the isthmus (Plate IV). From the upper border of the isthmus a small **pyramidal lobe** rises. It lies over the first tracheal ring and the arch of the cricoid cartilage.

TABLE OF LEVELS

In the following table of levels, the thoracic vertebrae are denoted by the letter T, with a subscript to indicate the particular vertebra in question. The lumbar vertebrae are denoted by the letter L in the same way. The intervertebral discs are denoted by the letter D with the subscripts 1 to 12, for those in the thoracic region, and 1 to 5 for those in the lumbar region. The number of the disc corresponds to the number of the vertebra immediately above. The tips of the spinous processes are denoted by the letter S. The same subscripts are used as in the case of the centra. R and C are the abbreviations used for rib, and costal cartilage. On account of the fact that the vertebral column is the axis of the skeleton, and especially on account of its being divided into alternate centra and discs which are convenient as points of reference it has been taken as the basis of this table. Only those points which are fixed and at the same time readily accessible, have been used in establishing levels upon the anterior body wall. The tips of the spinous processes have been used not because they are fixed and constant but because they are the only accessible points upon the posterior body wall.

The table is based upon imaginary horizontal sections

through the middle of each thoracic or lumbar vertebra or intervertebral disc. Each part is given at the level which comes nearest to it. Thus the upper border of an organ may be at the level of the upper border of a centrum, but will appear in the table as if cut by the section through the disc above, because that level shows more accurately the position of the part than the level through the middle of the centrum.

The first column of the table shows the level of the section, upon the vertebral column, which would pass through the parts named in the second column. The third column is a condensation of Quain's[1] table of levels and is included in this table to show what each plane would pass through were all the parts in their average position.

The skeletal parts are named first in each column, beginning each time at the anterior midline and going around the lateral body wall to the vertebral column.

[1] Thane, G. D. and Godlee, R. J., Quain's elements of anatomy. Appendix. Superficial and surgical anatomy. London, 1896.

TABLE OF STRUCTURES FOUND AT VARIOUS LEVELS

Centra and Discs	In This Subject	In Quain's Table
T_1	$R_1 S_1$. Apices of lungs. Summits of arches of subclavian arteries. Isthmus of thyreoid gland. Arch of thoracic duct.	R_1. Apices of lungs. Summits of arches of subclavian arteries.
D_1		
T_2	R_{1-2}. S_2. Lower limit of thyreoid gland. Formation of innominate veins. Bifurcation of innominate artery.	Inner end of clavicle. R_{1-2}. Bifurcation of innominate artery.
D_2	Upper border of sternal end of clavicle.	Upper edge of manubrium.
T_3	Upper border of sternum. Sternoclavicular articulations. R_{1-3}. S_3. Formation of vena cava superior. Origin of innominate, left subclavian and left common carotid arteries.	C_1. R_{1-3}. Innominate artery and veins. Formation of vena cava superior.
D_3	Upper border of first costal cartilages. Great fissure of left lung posteriorly. Highest point of pericardium.	Highest part of arch of aorta.
T_4	First sternochondral articulations. R_{2-4}. Arch of aorta. Great fissure of right lung posteriorly. Arch of azygos vein.	R_{2-4}. Arch of aorta.
D_4	Sternum across first intercostal spaces. Bifurcation of trachea. Upper limit of roots of lungs.	Bifurcation of trachea. Arch of azygos vein.

T_5	Second sternochondral articulations. R_{3-5}. S_4. Bronchi. Bifurcation of pulmonary artery. Pulmonary orifice. Highest part of right auricle.	Junction of manubrium with body of sternum. Second sternochondral articulations. C_2. R_{2-5}. Bronchi. Left pulmonary artery. Highest part of roots of lungs.
D_5	Sternum across second intercostal spaces. S_5. Bifurcation of fissure of right lung. Highest part of left auricle. End of vena cava superior.	Highesf part of heart.
T_6	Upper border of third costal cartilages. R_{3-6}. Aortic orifice. Upper part of mitral orifice.	R_{3-6}. Ascending aorta. Pulmonary orifice. Pulmonary artery. Left bronchus. End of vena cava superior.
D_6	Third sternochondral articulations. Highest part of tricuspid valve. Lower part of root of left lung.	Third sternochondral articulations.
T_7	Sternum across third intercostal spaces. R_{4-7}. S_6. Great fissure of left lung at midaxillary line.	R_{4-7}. Aortic orifice. Infundibulum of right ventricle. Lowest part of roots of lungs.
D_7	Fourth sternochondral articulations. Lower limit of mitral orifice. Lowest part of left auricle. Coronary sinus. Lowest point of superior lobe of right lung. Lower limit of root of right lung.	
T_8	Sternum at lower border of fourth costal cartilage. R_{5-8}. S_7. Left nipple.	Fourth sternochondral articutions. Nipple. C_4. R_{4-8}. Both auriculo-ventricular orifices.
D_8	Fifth sternochondral articulations. Lower limit of tricuspid orifice. Apex of left ventricular cavity. Right and	Right vault of diaphragm. Orifice of vena cava inferior. Right auriculo-ventricular orifice.

	left domes of diaphragm. Highest points of right and left lobes of the liver. Right nipple.	
T_9	Sixth and seventh sternochondral articulations. Xiphosternal articulation. C_{7-5}. R_{6-9}. S_8. Highest point of fundus of stomach. Lower border of heart in midline. Inferior vena caval opening through diaphragm.	Fifth and sixth sternochondral articulations. C_5. R_{5-9}. Liver. Left vault of diaphragm and fundus of stomach.
D_9	Base of xiphoid process. Apex of heart. Inferior margin of right lung and of left lung anteriorly. Upper pole of spleen. Oesophageal opening through diaphragm.	Xiphosternal articulation. Seventh sternochondral articulations. Lowest part of heart.
T_{10}	Middle of xiphoid process. C_{7-6}. R_{6-10}. S_9. Cardiac orifice of stomach.	Xiphoid process. C_{7-6}. R_{6-10}. Cardiac orifice of stomach.
D_{10}	Lower limit of left lung posteriorly.	Upper pole of spleen.
T_{11}	Apex of xiphoid process. C_7. R_{7-11}. S_{10}. Upper limit of hilus of spleen.	C_7. R_{7-11}. Lower margin of lung posteriorly. Upper end of left kidney. Suprarenal glands.
D_{11}	Junctions of seventh and eighth costal cartilages. S_{11}. Upper pole of left kidney. Apices of suprarenal glands.	Upper pole of right kidney.
T_{12}	C_{8-7}. R_{8-12}. S_{12}. Upper pole of right kidney. Upper border of body and tail of pancreas. Neck of gall bladder.	C_{8-7}. R_{7-12}. Foramen of Winslow. Pyloric orifice and first part of duodenum. Splenic flexure of colon.
D_{12}	Foramen of Winslow. Highest point of first part of duodenum.	Beginning of abdominal aorta and origin of coeliac axis.

L_1	Junctions of eighth and ninth costal cartilages. $R_{8\text{-}12}$. S_1. Inferior pole of spleen. Bases of suprarenal glands. Hilus of left kidney. Pyloric orifice. Duodenojejunal angle. Lower limit of body of pancreas. Fundus of gall bladder. Splenic flexure of colon. Beginning of abdominal aorta. Formation of portal vein.	C_8. $R_{8\text{-}12}$. Pyloric orifice and first part of duodenum. Hepatic flexure of colon. Pancreas. Receptaculum chyli. Hilus of kidneys. Renal arteries. Lower pole of spleen.
D_1		
L_2	C_9. $R_{9\text{-}12}$. S_2. Hilus of right kidney. Hepatic flexure of colon. Receptaculum chyli.	C_9. $R_{9\text{-}11}$. Head of pancreas. Duodenojejunal angle.
D_2	$C_{10\text{-}12}$. Transverse duodenum. Head of pancreas. Lower pole of left kidney.	Lower pole of left kidney.
L_3	S_3. Lowest point of transverse duodenum. Lowest point of head of pancreas. Lowest point of liver.	Infracostal plane. Third part of duodenum. Lower pole of right kidney. Lowest point of liver.
D_3	Lower pole of right kidney.	Umbilicus.
L_4	Umbilicus. S_4. Highest point of iliac crests. Bifurcation of aorta.	Highest point of iliac crest. Bifurcation of aorta.
D_4	Ileocolic valve. Formation of vena cava inferior.	
L_5	Caecum. Appendix. Bifurcation of common iliac arteries.	Formation of vena cava inferior.
D_5	Anterior superior iliac spines.	Anterior superior iliac spines. Bifurcation of common iliac arteries.

PLATES

EXPLANATION OF REFERENCE NUMBERS USED IN THE PLATES

[BNA] terms are used in the table. English equivalents are given in parentheses. A dash after a number indicates that there is no specific [BNA] term for the part.

2. N. phrenicus.
3. N. vagus.
3A. N. laryngeus inferior.
3B. Plexus oesophageus posterior.
3C. Plexus oesophageus anterior.
4. Truncus sympathicus.
5. V. jugularis externa.
6. A. et V. thyreoidea superior.
7. A. et V. vertebralis.
8. N. cervicalis V.
9. N. cervicalis VI.
10. N. cervicalis VII.
12. N. cervicalis VIII.
13. A. et V. transversa scapulae.
14. A. et V. transversa colli.
16. N. thoracalis I.
17. } Plexus brachialis { (upper trunk of brachial plexus).
18. } { (anterior division of upper trunk).
19. } { (posterior division of upper trunk).
20. A. et V. cervicalis ascendens.
21. A. thyreoidea inferior.
21A. V. thyreoidea inferior.
22. Ductus thoracicus.
23. A. subclavia.
24. A. et V. mammaria interna.
25. ————————(lateral infracostal vessels).
26. Fasciculus posterior (posterior cord of brachial plexus).
27. Fasciculus medialis (inner cord of brachial plexus).
28. Fasciculus lateralis (outer cord of brachial plexus).
29. N. cutaneus antibrachii medialis (internal cutaneous nerve).
30. N. radialis (musculospiral nerve).
31. N. cutaneus brachii posterior.
32. Ramus muscularis nervi radialis.
33. N. axillaris (circumflex nerve).
34. N. radialis (separated from main nerve by a small vein at this level).
35. A. axillaris.
36. V. brachialis (external vein of brachial venae comites).
37. A. et V. thoracalis lateralis.
38. V. cephalica.
41. N. musculocutaneus.
42. N. ulnaris.

43. } N. medianus { (outer head of median nerve).
44. } { (inner head of median nerve).
45. } { (median nerve).
46. A. subscapularis.
46A. A. thoracodorsalis (long thoracic artery).
47. A. circumflexa scapulae.
48. V. circumflexa humeri posterior.
49. V. azygos.
50. V. hemiazygos accessoria.
51. V. hemiazygos.
52. N. splanchnicus major.
53. A. phrenica inferior.
54. Ductus hepaticus.
55. Ductus cysticus.
56. Ductus choledochus.
58. A. hepatica propria.
59. A. gastrica dextra.
60. A. gastroduodenalis.
61. Ureter.
62. V. suprarenalis.
63. A. mesenterica superior.
64. V. mesenterica superior.
65. V. mesenterica inferior.
65A. A. mesenterica inferior.
66. A. et V. lienalis.
67. A. et V. spermatica interna.
68. N. thoracalis XII.
69. N. lumbalis I.
70. N. lumbalis II.
71. N. lumbalis III.
72. ———— (common trunk formed by second and third lumbar nerves).
73. N. lumbalis IV.
74. N. obturatorius.
75. N. femoralis (anterior crural).
76. N. lumbalis V.
77. Truncus lumbosacralis.
77A. ————(branch of fourth lumbar nerve to lumbosacral cord).
78. N. sacralis I.
79. N. sacralis II.
80. N. sacralis III.
81. Funiculus spermaticus (spermatic cord).
82. Sinus coronarius.
83. A. coronaria [cordis] dextra.
84. Ramus descendens anterior arteriæ coronariæ [cordis] sinistræ.
84A. Ramus circumflexus arteriæ coronariæ [cordis] sinistræ.
85. Ductus deferens.

PLATE I

PLATE I

Plate I is from the upper surface of section I which passes through the intervertebral disc (Fibrocartilago intervertebralis IV) between the fourth and fifth cervical vertebrae posteriorly and through the thyreoid and arytenoid cartilages anteriorly. The dotted line is the outline of section II which is 1.3 cm. below this plane and shows how rapidly the body expands in this region.

The plane of the section is not horizontal but is 4.4 cm. lower in front than behind, and is a little lower on the right than on the left side.

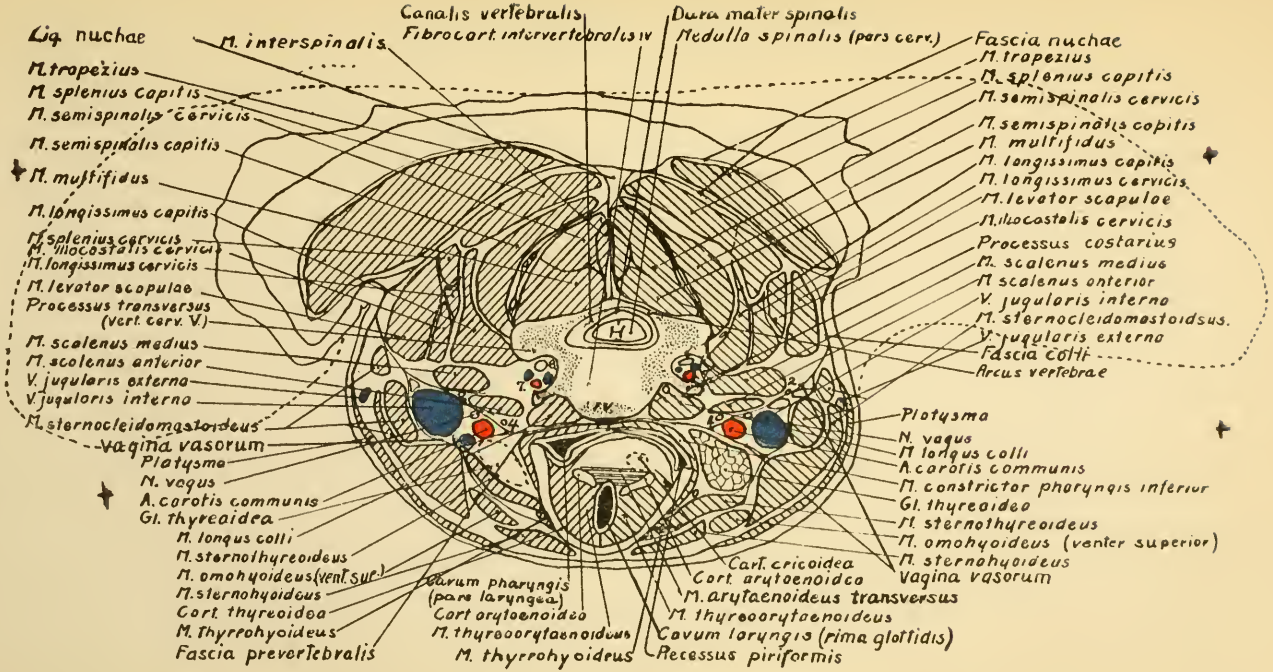
Lig. nuchae
M. interspinalis
Canalis vertebralis
Fibrocart. intervertebralis IV
Dura mater spinalis
Medulla spinalis (pars cerv.)
M. trapezius
M. splenius capitis
M. semispinalis cervicis
M. semispinalis capitis
M. multifidus
M. longissimus capitis
M. splenius cervicis
M. iliocostalis cervicis
M. longissimus cervicis
M. levator scapulae
Processus transversus (vert. cerv. V.)
M. scalenus medius
M. scalenus anterior
V. jugularis externa
V. jugularis interna
M. sternocleidomastoideus
Vagina vasorum
Platysma
N. vagus
A. carotis communis
Gl. thyreoidea
M. longus colli
M. sternothyreoideus
M. omohyoideus (venter sup.)
M. sternohyoideus
Cart. thyreoidea
M. thyrohyoideus
Fascia prevertebralis
Fascia nuchae
M. trapezius
M. splenius capitis
M. semispinalis cervicis
M. semispinalis capitis
M. multifidus
M. longissimus capitis
M. longissimus cervicis
M. levator scapulae
M. iliocostalis cervicis
Processus costarius
M. scalenus medius
M. scalenus anterior
V. jugularis interna
M. sternocleidomastoideus
V. jugularis externa
Fascia colli
Arcus vertebrae
Platysma
N. vagus
M. longus colli
A. carotis communis
M. constrictor pharyngis inferior
Gl. thyreoidea
M. sternothyreoideus
M. omohyoideus (venter superior)
M. sternohyoideus
Vagina vasorum
Cart. cricoidea
Cart. arytaenoidea
M. arytaenoideus transversus
M. thyreoarytaenoideus
Cavum laryngis (rima glottidis)
Recessus piriformis
Cavum pharyngis (pars laryngea)
Cart. arytaenoidea
M. thyreoarytaenoideus
M. thyrohyoideus

PLATE I.

PLATE II

PLATE II

Plate II is from a section through the intervertebral disc (Fibrocartilago intervertebralis V) between the fifth and sixth cervical vertebrae posteriorly, the upper part of the lamina of the cricoid cartilage anteriorly and the upper surface of the acromial end of the clavicles laterally. The upper surface of this section is 1.3 cm. posteriorly and .4 cm. anteriorly below that of section I, so that the anterior margin is 3.5 cm. below the posterior.

The right lobe of the thyreoid gland is small at the surface of the section but enlarges a little lower down and projects backward and inward into the space, indicated by the dotted outline, between the pharynx and the prevertebral fascia.

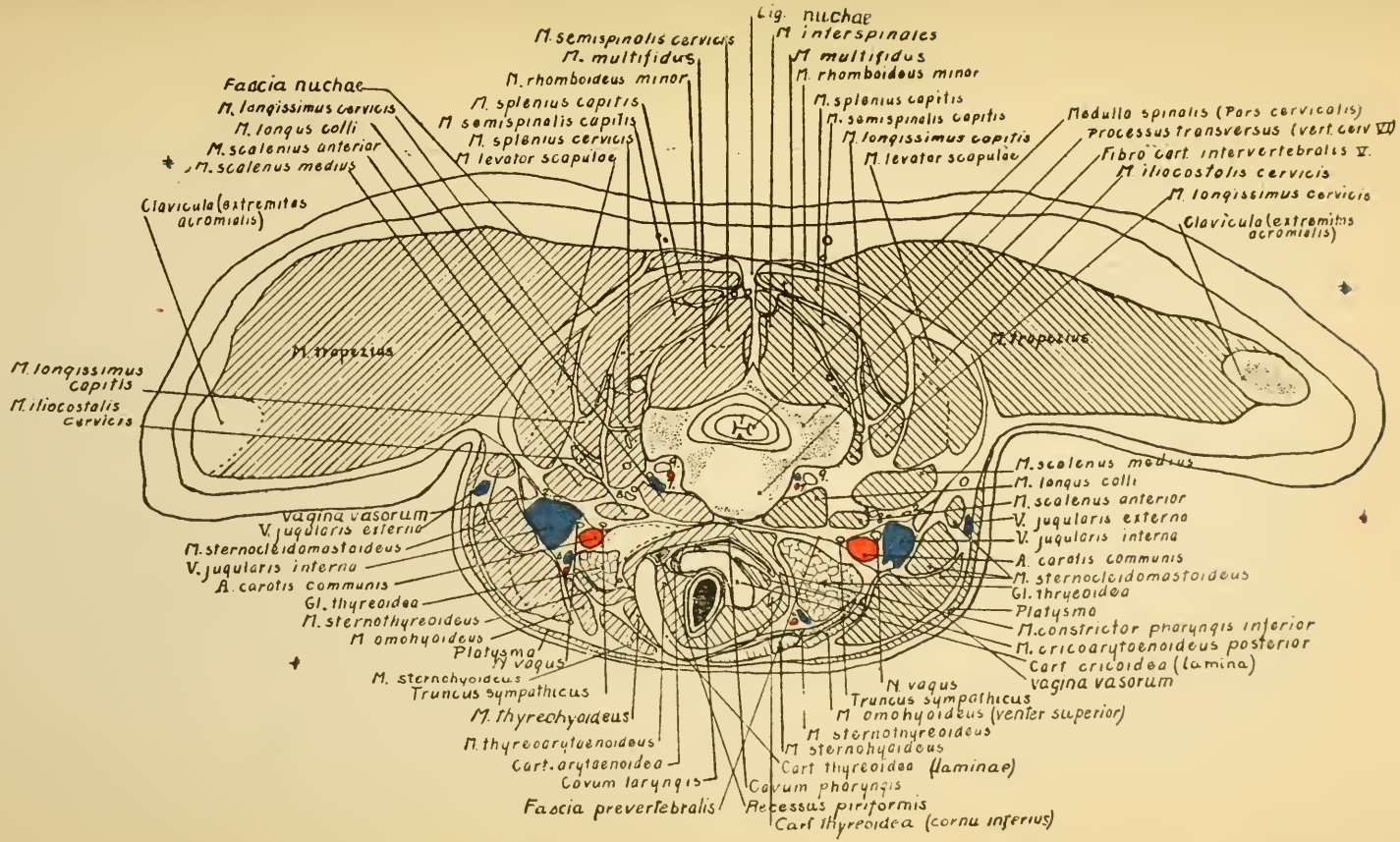
Lig. nuchae
M. semispinalis cervicis
M. multifidus
M. rhomboideus minor
M. splenius capitis
M. semispinalis capitis
M. splenius cervicis
M. levator scapulae
M. interspinales
M. multifidus
M. rhomboideus minor
M. splenius capitis
M. semispinalis capitis
M. longissimus capitis
M. levator scapulae
Fascia nuchae
M. longissimus cervicis
M. longus colli
M. scalenus anterior
M. scalenus medius
Clavicula (extremitas acromialis)
Medulla spinalis (Pars cervicalis)
Processus transversus (vert. cerv. VI)
Fibro cart. intervertebralis V.
M. iliocostalis cervicis
M. longissimus cervicis
Clavicula (extremitas acromialis)
M. trapezius
M. trapezius
M. longissimus capitis
M. iliocostalis cervicis
M. scalenus medius
M. longus colli
M. scalenus anterior
V. jugularis externa
V. jugularis interna
A. carotis communis
M. sternocleidomastoideus
Gl. thyreoidea
Platysma
M. constrictor pharyngis inferior
M. cricoarytaenoideus posterior
Cart. cricoidea (lamina)
Vagina vasorum
Vagina vasorum
V. jugularis externa
M. sternocleidomastoideus
V. jugularis interna
A. carotis communis
Gl. thyreoidea
M. sternothyreoideus
M. omohyoideus
Platysma
N. vagus
M. sternohyoideus
Truncus sympathicus
M. thyrechyoideus
M. thyreoarytaenoideus
Cart. arytaenoidea
Cavum laryngis
Fascia prevertebralis
N. vagus
Truncus sympathicus
M. omohyoideus (venter superior)
M. sternothyreoideus
M. sternohyoideus
Cart. thyreoidea (laminae)
Cavum pharyngis
Recessus piriformis
Cart. thyreoidea (cornu inferius)

PLATE II.

PLATE III

PLATE III

Plate III is from a section through the upper part of the seventh cervical vertebra posteriorly, the arch of the cricoid cartilage (Arcus cart. cricoideae) anteriorly and the upper part of the heads of the humeri laterally. The plane of section is 1.8 cm. posteriorly and 1.1 cm. anteriorly below section II so that the anterior margin is 2.8 cm. below the posterior.

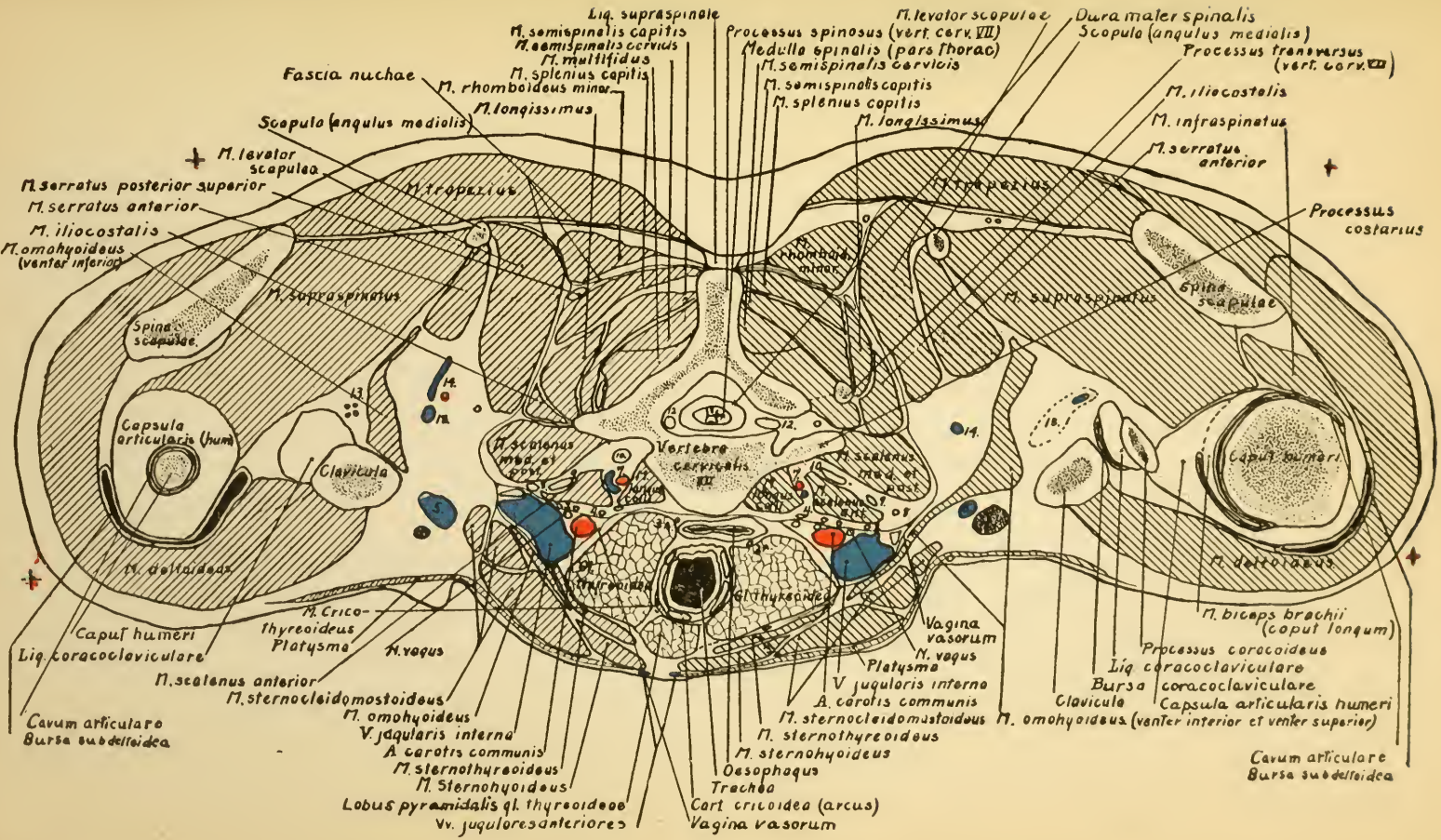
Lig. supraspinale
M. semispinalis capitis
M. semispinalis cervicis
M. multifidus
M. splenius capitis
Processus spinosus (vert. cerv. VII)
Medulla spinalis (pars thorac)
M. semispinalis cervicis
M. semispinalis capitis
M. splenius capitis
M. longissimus
M. levator scapulae
Dura mater spinalis
Scapula (angulus medialis)
Processus transversus (vert. cerv. VII)
Fascia nuchae
M. rhomboideus minor
M. longissimus
M. iliocostalis
M. infraspinatus
M. serratus anterior
M. levator scapulae
M. serratus posterior superior
M. serratus anterior
M. iliocostalis
M. omohyoideus (venter inferior)
M. trapezius
M. trapezius
Processus costarius
M. rhomboid. minor
M. supraspinatus
M. supraspinatus
Spina scapulae
Spina scapulae
Capsula articularis (hum)
Clavicula
M. scalenus med. et post.
Vertebra cervicalis VII
M. scalenus med. et post.
Caput humeri
M. deltoideus
M. deltoideus
M. Crico-thyreoideus
Platysma
N. vagus
Caput humeri
Lig. coracoclaviculare
M. scalenus anterior
M. sternocleidomastoideus
M. omohyoideus
V. jugularis interna
A. carotis communis
M. sternothyreoideus
M. Sternohyoideus
Lobus pyramidalis gl. thyreoideae
Vv. jugulares anteriores
Oesophagus
Trachea
Cart. cricoidea (arcus)
Vagina vasorum
Vagina vasorum
N. vagus
Platysma
V. jugularis interna
A. carotis communis
M. sternocleidomastoideus
M. sternothyreoideus
M. sternohyoideus
M. omohyoideus (venter inferior et venter superior)
M. biceps brachii (caput longum)
Processus coracoideus
Lig. coracoclaviculare
Bursa coracoclaviculare
Clavicula
Capsula articularis humeri
Cavum articulare
Bursa subdeltoidea
Cavum articulare
Bursa subdeltoidea

PLATE III.

PLATE IV

PLATE IV

Plate IV is from a section through the upper half of the first thoracic vertebra posteriorly, the middle of the clavicles anteriorly and the middle of the glenoid cavities of the scapulae laterally. The plane of the section is 1.3 cm. posteriorly and 1.1 cm. anteriorly below that of section III so that the anterior margin is 2.6 cm. below the posterior.

The thoracic duct is cut through the uppermost part of the arch. The internal part is the ascending limb, the external the descending limb. A valve is present at the junction of the two limbs.

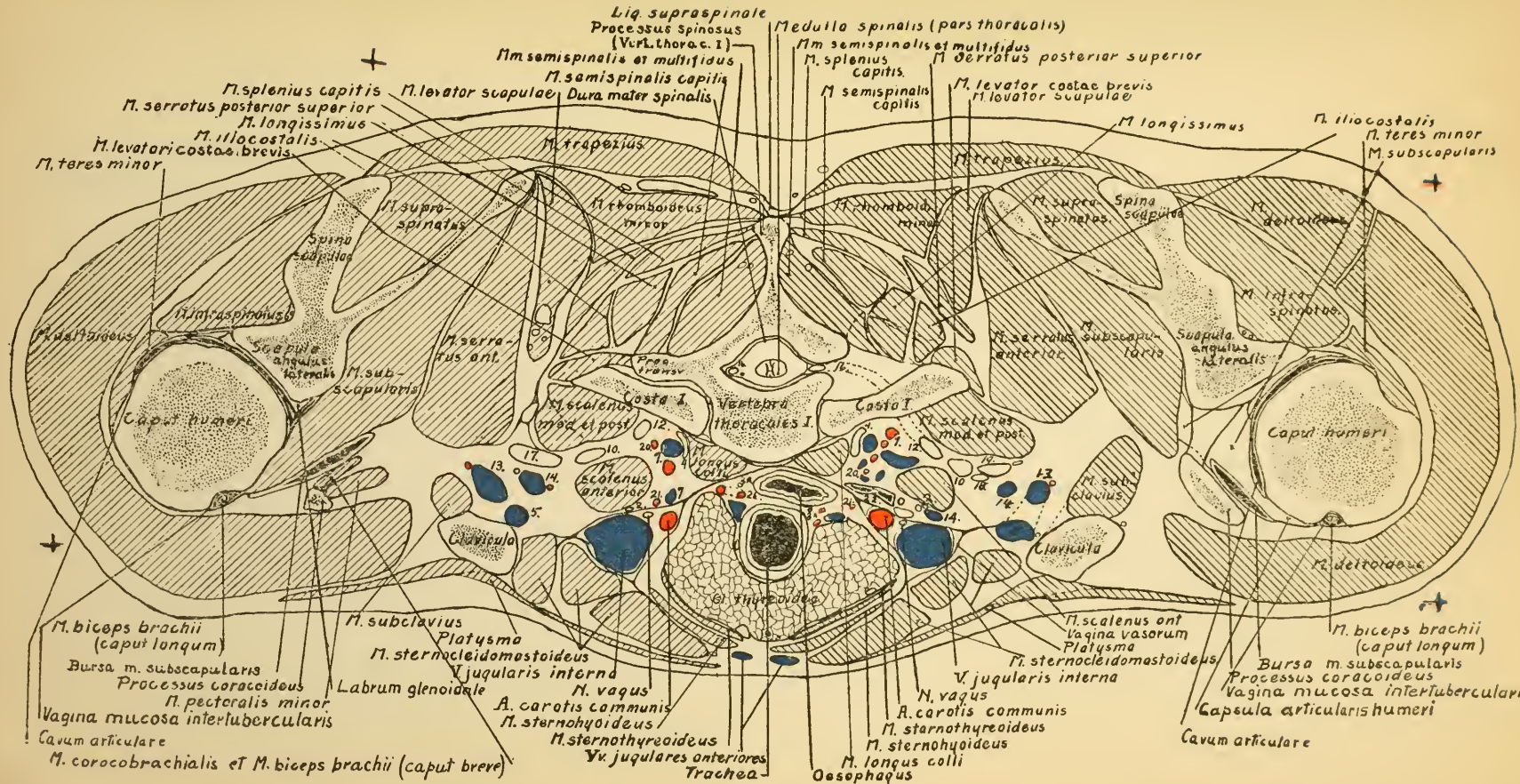
Lig. supraspinale
Processus spinosus (Vert. thorac. I)
Mm semispinalis et multifidus
M. semispinalis capitis
Dura mater spinalis
Medulla spinalis (pars thoracalis)
Mm semispinalis et multifidus
M. splenius capitis
M. semispinalis capitis
M. serratus posterior superior
M. levator costae brevis
M. levator scapulae
M. splenius capitis
M. serratus posterior superior
M. longissimus
M. iliocostalis
M. levatori costae brevis
M. teres minor
M. longissimus
M. iliocostalis
M. teres minor
M. subscapularis
M. trapezius
M. trapezius
M. supra-spinatus
M. rhomboideus minor
M. rhomboid. minor
M. supra-spinatus
Spina scapulae
M. deltoideus
Spina scapulae
M. infra-spinatus
M. infra-spinatus
M. deltoideus
Scapula angulus lateralis
M. sub-scapularis
M. serratus ant.
Proc. transv.
M. serratus anterior
M. subscapularis
Scapula angulus lateralis
Caput humeri
Caput humeri
Costa I.
Vertebra thoracales I.
Costa I.
M. scalenus med. et post.
M. scalenus med. et post.
M. longus colli
M. scalenus anterior
M. subclavius
Clavicula
Clavicula
M. deltoideus
Gl. thyreoidea
M. biceps brachii (caput longum)
Bursa m. subscapularis
Processus coracoideus
M. pectoralis minor
Vagina mucosa intertubercularis
Cavum articulare
M. corocobrachialis et M. biceps brachii (caput breve)
M. subclavius
Platysma
M. sternocleidomastoideus
V. jugularis interna
Labrum glenoidale
N. vagus
A. carotis communis
M. sternohyoideus
M. sternothyreoideus
Vv. jugulares anteriores
Trachea
Oesophagus
M. longus colli
M. sternohyoideus
M. sternothyreoideus
A. carotis communis
N. vagus
V. jugularis interna
M. sternocleidomastoideus
Platysma
Vagina vasorum
M. scalenus ant.
M. biceps brachii (caput longum)
Bursa m. subscapularis
Processus coracoideus
Vagina mucosa intertubercularis
Capsula articularis humeri
Cavum articulare

PLATE V.

PLATE V

Plate V is from a section through the intervertebral disc (Fibrocartilago intervertebralis I) between the first and second thoracic vertebrae posteriorly, through the inner third of the clavicles anteriorly, and through the lower part of the glenoid cavities of the scapulae laterally. The plane of the section is 1.7 cm. anteriorly and 1.1 cm. posteriorly below section IV, hence the anterior margin is 3.2 cm. lower than the posterior.

The axillary veins are not cut except where other veins open into them, but each is easily traced at the surface of the section, and is indicated in the plate by dotted lines.

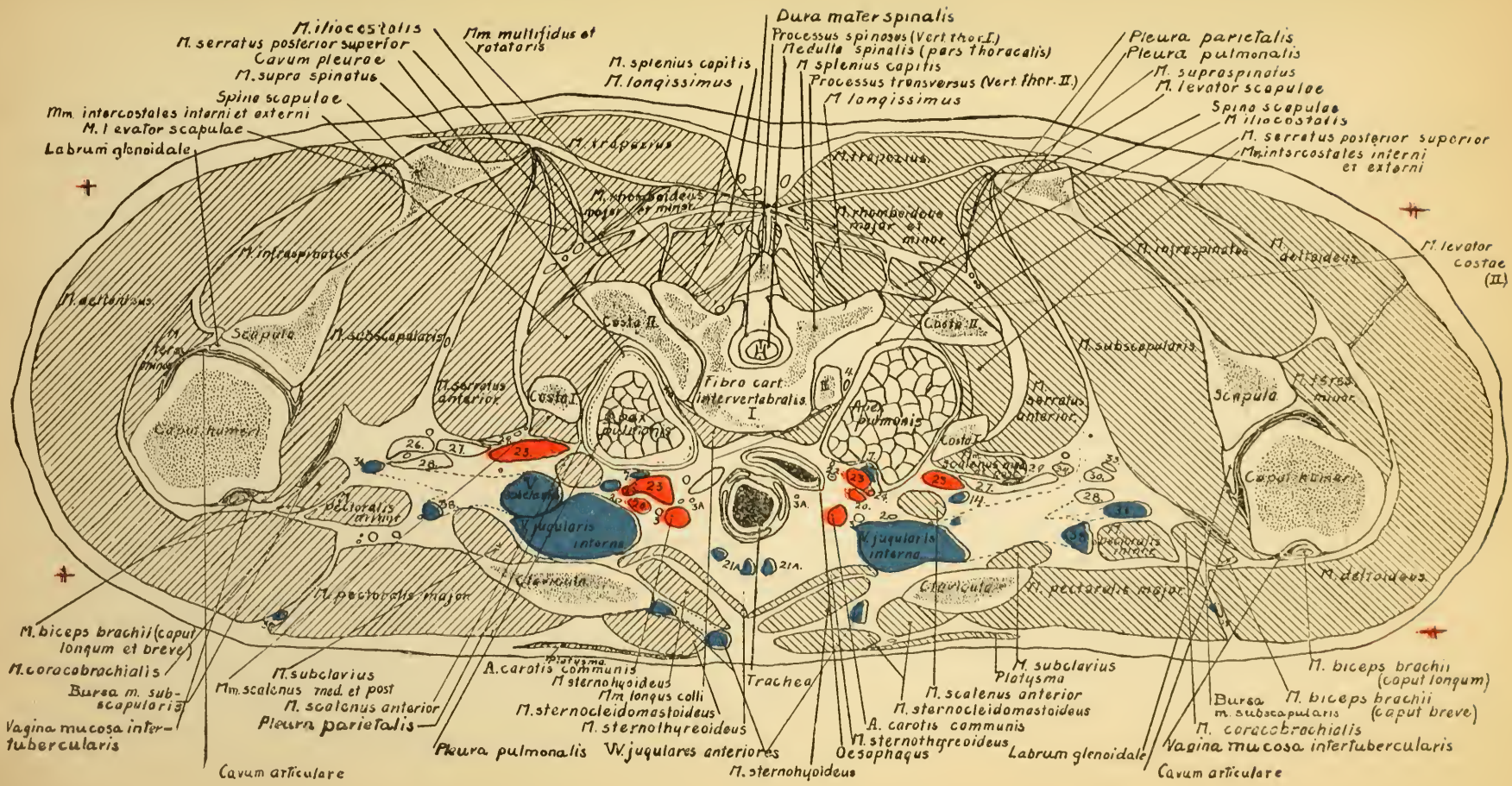
Dura mater spinalis
Processus spinosus (Vert. thor. I.)
Medulla spinalis (pars thoracalis)
M. splenius capitis
Processus transversus (Vert. thor. II.)
M. longissimus
M. iliocostalis
M. serratus posterior superior
Cavum pleurae
M. supra spinatus
Spina scapulae
Mm. intercostales interni et externi
M. levator scapulae
Labrum glenoidale
Mm. multifidus et rotatoris
M. splenius capitis
M. longissimus
Pleura parietalis
Pleura pulmonalis
M. supraspinatus
M. levator scapulae
Spina scapulae
M. iliocostalis
M. serratus posterior superior
Mm. intercostales interni et externi
M. trapezius
M. rhomboideus major et minor
M. infraspinatus
M. deltoideus
M. levator costae (II)
M. deltoideus
Scapula
M. subscapularis
Costa II
Costa I
Fibro cart. intervertebralis I
Apex pulmonis
M. serratus anterior
Caput humeri
M. pectoralis minor
V. subclavia
V. jugularis interna
Clavicula
M. pectoralis major
M. biceps brachii (caput longum et breve)
M. coracobrachialis
Bursa m. subscapularis
Vagina mucosa intertubercularis
Cavum articulare
M. subclavius
Mm. scalenus med. et post
M. scalenus anterior
Pleura parietalis
Pleura pulmonalis
A. carotis communis
M. sternohyoideus
Mm. longus colli
M. sternocleidomastoideus
M. sternothyreoideus
W. jugulares anteriores
Trachea
M. sternohyoideus
Oesophagus
M. sternothyreoideus
A. carotis communis
M. sternocleidomastoideus
M. scalenus anterior
Platysma
M. subclavius
Labrum glenoidale
M. biceps brachii (caput longum)
M. biceps brachii (caput breve)
Bursa m. subscapularis
M. coracobrachialis
Vagina mucosa intertubercularis
Cavum articulare

PLATE VI

PLATE VI

Plate VI is from a section through the lower part of the second thoracic vertebra posteriorly, the sternoclavicular articulations anteriorly, and through the infraglenoid tubercles, and below the spines of the scapulae laterally. The plane of the section is 1.7 cm. anteriorly and 2 cm. posteriorly below section V so that the anterior margin is 2.9 cm. lower than the posterior.

The left innominate vein (V. anonyma sinistra) crosses the median line in this section and unites with the right innominate vein (V. anonyma dextra) about 2 cm. to the right of the midline. Its course across the mediastinal space is indicated by dotted lines.

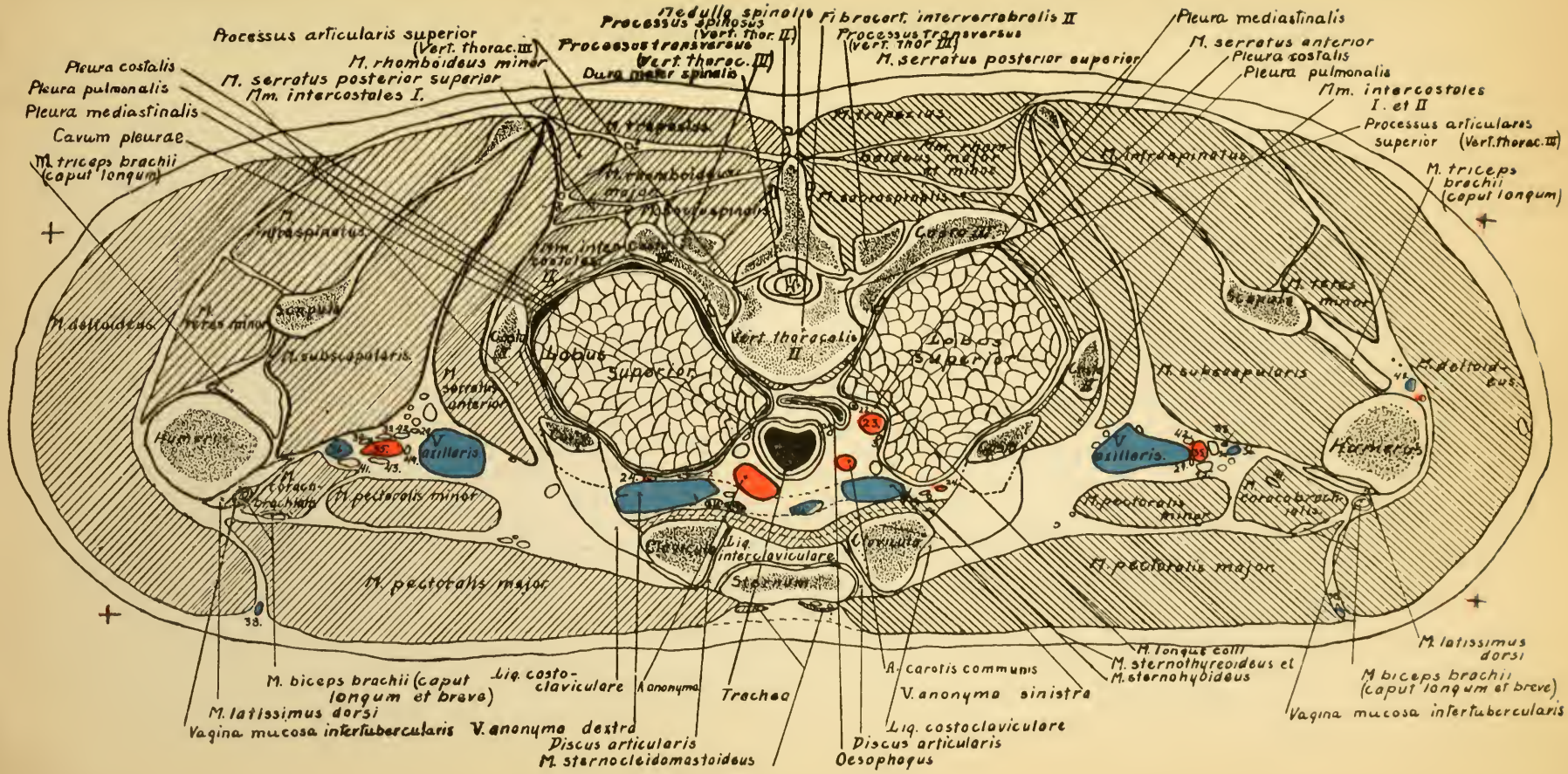
Processus articularis superior (Vert. thorac. III)
M. rhomboideus minor
M. serratus posterior superior
Mm. intercostales I.
Pleura costalis
Pleura pulmonalis
Pleura mediastinalis
Cavum pleurae
M. triceps brachii (caput longum)
Medulla spinalis
Processus spinosus (Vert. thor. II)
Processus transversus (Vert. thorac. III)
Dura mater spinalis
Fibrocart. intervertebralis II
Processus transversus (Vert. thor III)
M. serratus posterior superior
Pleura mediastinalis
M. serratus anterior
Pleura costalis
Pleura pulmonalis
Mm. intercostales I. et II
Processus articulares superior (Vert. thorac. III)
M. triceps brachii (caput longum)
M. trapezius
M. rhomboideus major
M. sacrospinalis
M. intraspinatus
Costa III
Scapula
M. teres minor
M. deltoideus
M. subscapularis
M. serratus anterior
Lobus superior
Vert. thoracalis II
Costa II
Humerus
V. axillaris
M. coracobrachialis
M. pectoralis minor
M. pectoralis major
Clavicula
Liq. interclaviculare
Sternum
M. biceps brachii (caput longum et breve)
M. latissimus dorsi
Vagina mucosa intertubercularis
Liq. costoclaviculare
A. anonyma
V. anonyma dextra
Discus articularis
M. sternocleidomastoideus
Trachea
A. carotis communis
V. anonyma sinistra
Liq. costoclaviculare
Discus articularis
Oesophagus
M. longus colli
M. sternothyreoideus et
M. sternohyoideus
M. latissimus dorsi
M. biceps brachii (caput longum et breve)
Vagina mucosa intertubercularis

PLATE VII

PLATE VII

Plate VII is from a section through the uppermost part of the fourth thoracic vertebra posteriorly and the upper part of the first intercostal spaces anteriorly. The plane of the section is 2.1 cm. anteriorly and 2.8 cm. posteriorly below the last section. The anterior margin is 2.2 cm. lower than the posterior.

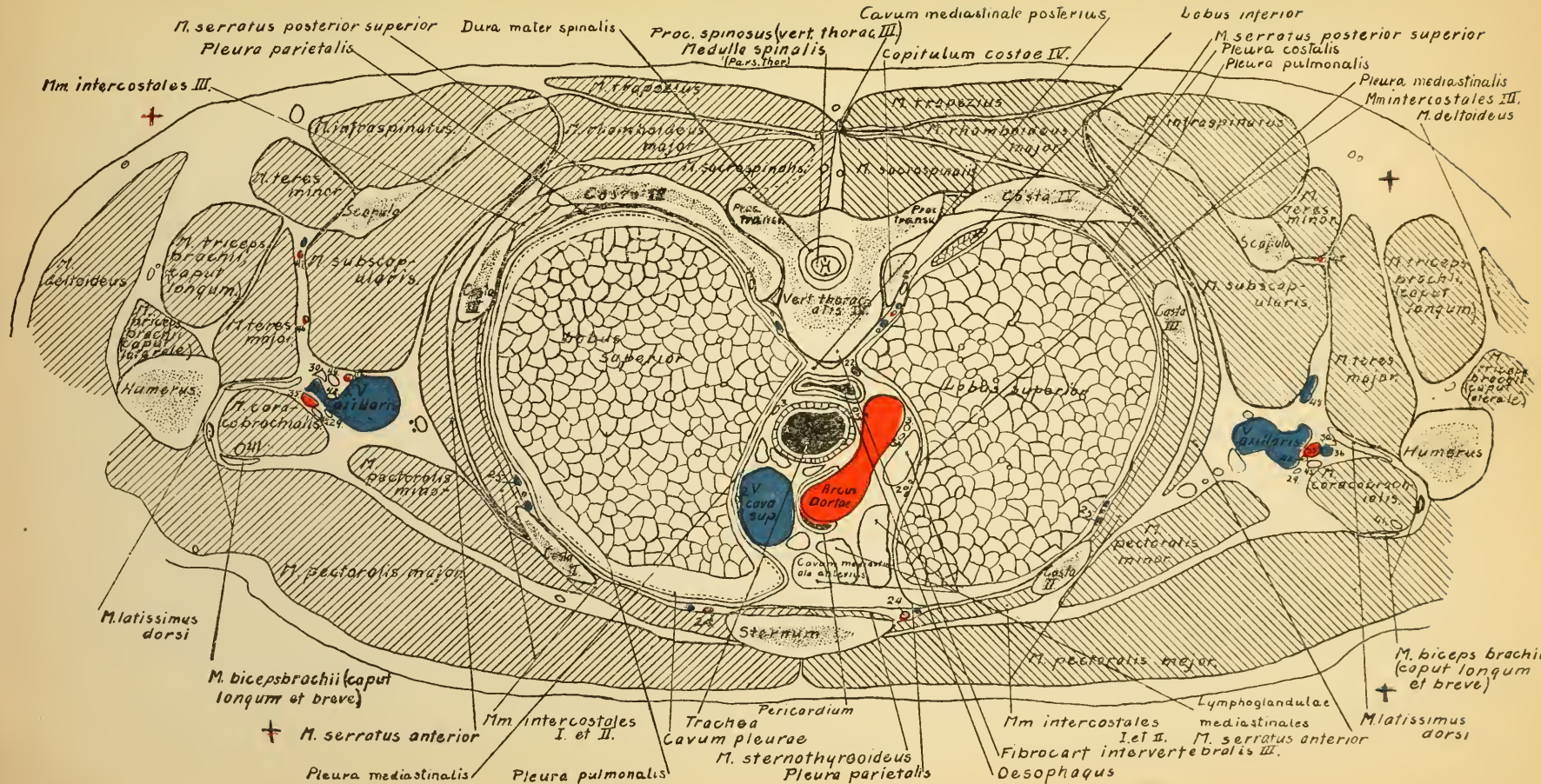
M. serratus posterior superior
Pleura parietalis
Dura mater spinalis
Proc. spinosus (vert. thorac. III.)
Medulla spinalis (Pars. thor.)
Cavum mediastinale posterius
Capitulum costae IV.
Lobus inferior
M. serratus posterior superior
Pleura costalis
Pleura pulmonalis
Pleura mediastinalis
Mm intercostales III.
M. deltoideus
Mm. intercostales III.
M. trapezius
M. infraspinatus
M. rhomboideus major
M. sacrospinalis
M. teres minor
Scapula
M. triceps brachii (caput longum)
M. subscapularis
M. deltoideus
M. triceps brachii (caput laterale)
M. teres major
Humerus
M. coracobrachialis
V. axillaris
M. pectoralis minor
M. pectoralis major
M. latissimus dorsi
M. bicepsbrachii (caput longum et breve)
M. serratus anterior
Mm. intercostales I. et II.
Pleura mediastinalis
Pleura pulmonalis
Trachea
Cavum pleurae
Pericardium
M. sternothyreoideus
Pleura parietalis
Oesophagus
Fibrocart intervertebralis III.
Mm intercostales I. et II.
Lymphoglandulae mediastinales
M. serratus anterior
M. latissimus dorsi
M. biceps brachii (caput longum et breve)
Costa III
Costa IV
Costa II
Vert. thoracalis IV.
Lobus superior
Arcus aortae
V. cava sup.
Cavum mediastinale anterius
Sternum
Costa II
Costa III
Costa IV
Proc. transv.
Proc. transv.
M. pectoralis minor
M. pectoralis major
M. subscapularis
M. teres minor
M. triceps brachii (caput longum)
M. triceps brachii (caput laterale)
M. teres major
V. axillaris
M. coracobrachialis
Humerus

PLATE VIII

PLATE VIII

Plate VIII is from the upper surface of a section through the upper third of the body of the fifth thoracic vertebra posteriorly, and the lower part of the second intercostal space anteriorly. The plane of the section is 2.8 cm. below that of the preceding section. The anterior margin is 2.2 cm. lower than the posterior.

The posterior semilunar valve of the pulmonary orifice is left in this section, the right and left anterior semilunar valves were removed with the section above. The pulmonary artery lies almost entirely in the section above this.

The pericardial cavity, though wide in this section, is very shallow, being filled by the widening out of the right auricle and ventricle at a slightly lower level, and the appearance of the left auricular appendix in the left posterior part of the cavity.

The vena cava superior enters the right auricle (Atrium dextrum) about .5 cm. below the surface of the section. The section is through the apex of the right auricular appendix.

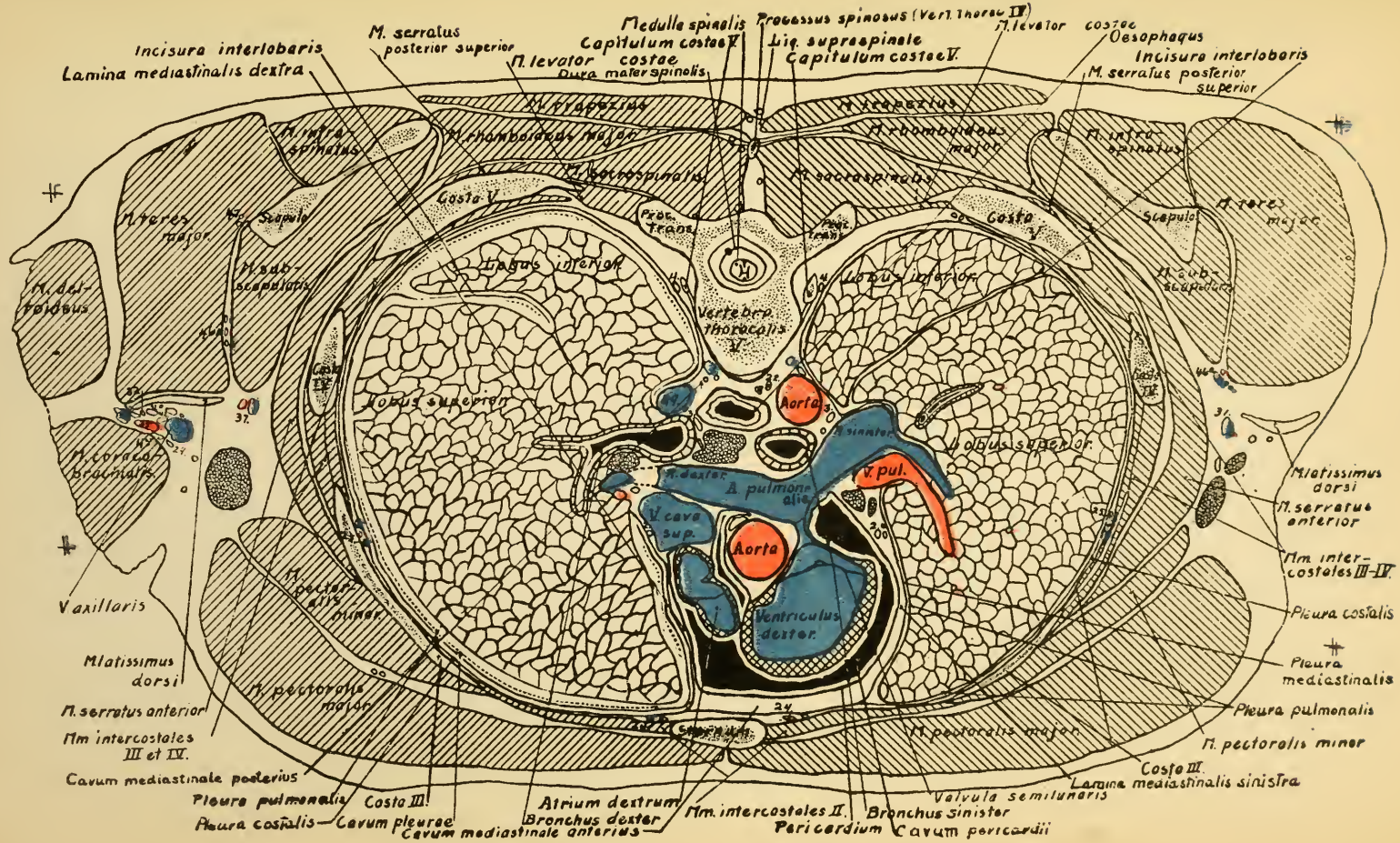
Incisura interlobaris
Lamina mediastinalis dextra
M. serratus posterior superior
Medulla spinalis
Capitulum costae V
M. levator costae
Dura mater spinalis
Processus spinosus (Ver.) Thorac. IV
Lig. supraspinale
Capitulum costae V.
M. levator costae
Oesophagus
Incisura interlobaris
M. serratus posterior superior
M. trapezius
M. rhomboideus major
M. infra-spinatus
M. sacrospinalis
Costa V.
Proc. trans.
Scapula
M. teres major
M. sub-scapularis
M. del-toideus
Lobus inferior
Vertebra thoracalis V.
Lobus superior
Aorta
N. sinister
N. dexter
A. pulmonalis
V. pul.
V. cava sup.
Ventriculus dexter
M. coraco-brachialis
V. axillaris
M. latissimus dorsi
M. serratus anterior
Mm. intercostales III et IV.
M. pectoralis minor
M. pectoralis major
Cavum mediastinale posterius
Pleura pulmonalis
Pleura costalis
Costa III.
Cavum pleurae
Cavum mediastinale anterius
Atrium dextrum
Bronchus dexter
Mm. intercostales II.
Pericardium
Bronchus sinister
Cavum pericardii
Valvula semilunaris
Lamina mediastinalis sinistra
Costa III.
M. pectoralis minor
M. pectoralis major
Pleura pulmonalis
Pleura mediastinalis
Pleura costalis
Mm. intercostales III-IV.
M. serratus anterior
M. latissimus dorsi

PLATE VIII.

PLATE IX

PLATE IX

Plate IX is from the upper surface of a section through the upper third of the body of the sixth thoracic vertebra posteriorly and the upper part of the articulations of the third costal cartilages with the sternum anteriorly. The plane of the section is 1.8 cm. anteriorly and 2.2 cm. posteriorly, below the plane of the last section. The anterior margin is 1.8 cm. lower than the posterior.

The cavity of the left auricle is divided into an anterior and a posterior chamber by a peculiar thin fibrous septum, perforated by several foramina, which permitted the free passage of blood through the auricle. The lower portion of the septum is shown in Plate X. This anomaly is fully described in the Journal of Anatomy and Physiology, XXXIX. p. 69.

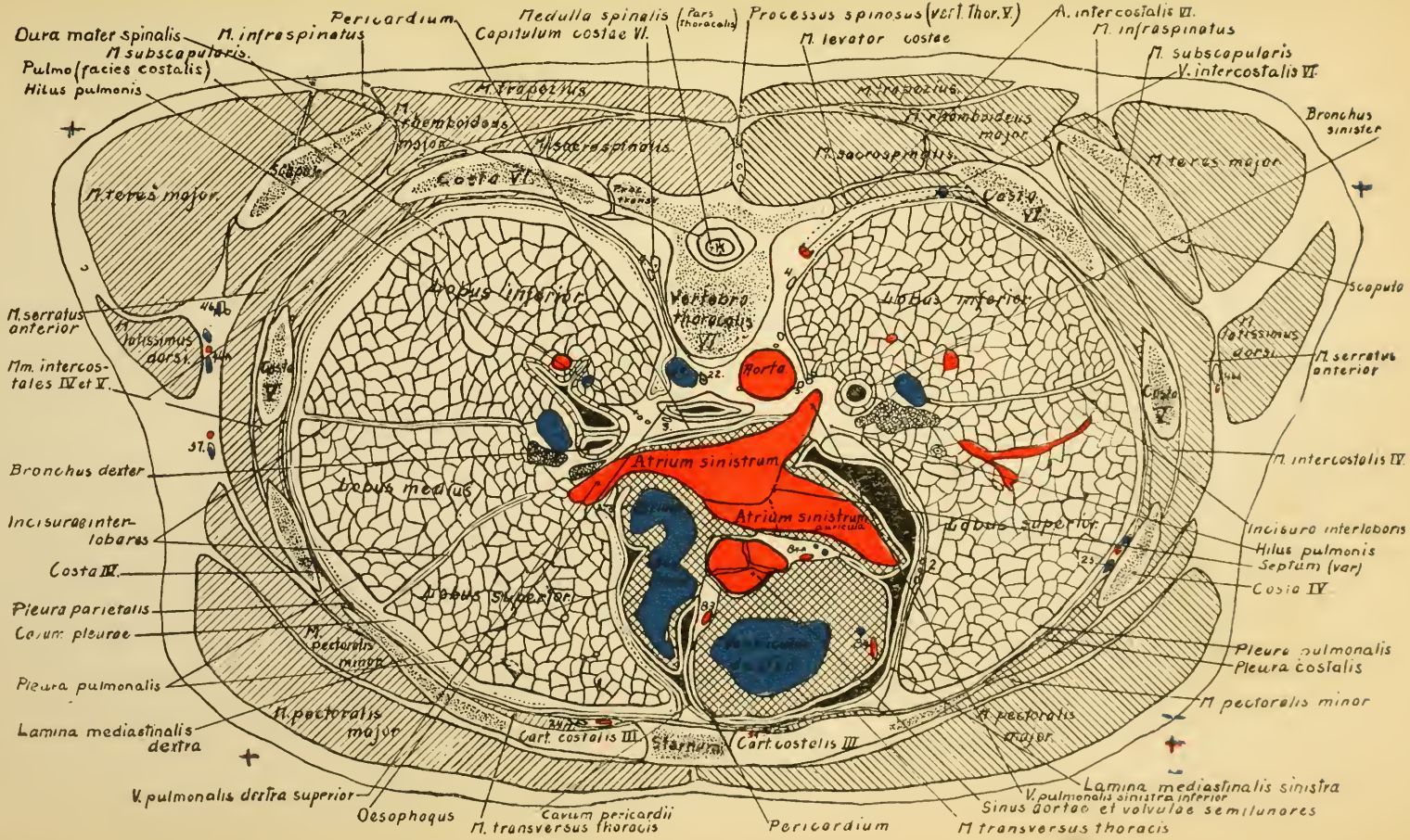
Dura mater spinalis
M. infraspinatus
Pericardium
Medulla spinalis (Pars thoracalis)
Capitulum costae VI.
Processus spinosus (vert. Thor. V.)
M. levator costae
A. intercostalis VI.
M. infraspinatus
M. subscapularis
V. intercostalis VI.
M. subscapularis
Pulmo (facies costalis)
Hilus pulmonis
M. trapezius
M. rhomboideus major
M. sacrospinalis
Costa VI.
Scapula
M. teres major
Bronchus sinister
M. teres major
Costa VI.
Lobus inferior
Vertebra thoracalis VI.
Lobus inferior
Scapula
M. serratus anterior
M. latissimus dorsi
Mm. intercostales IV et V.
Costa V.
Aorta
M. latissimus dorsi
M. serratus anterior
Costa V.
Atrium sinistrum
M. intercostalis IV.
Bronchus dexter
Lobus medius
Atrium sinistrum
Incisurae interlobares
Lobus superior
Incisura interlobaris
Hilus pulmonis
Septum (var)
Costa IV.
Costa IV.
Lobus superior
Pleura parietalis
Cavum pleurae
M. pectoralis minor
Pleura pulmonalis
Pleura costalis
Pleura pulmonalis
M. pectoralis minor
M. pectoralis major
Lamina mediastinalis dextra
Cart. costalis III.
Sternum
Cart. costalis III.
M. pectoralis major
Lamina mediastinalis sinistra
V. pulmonalis dextra superior
V. pulmonalis sinistra inferior
Sinus aortae et valvulae semilunares
Oesophagus
Cavum pericardii
M. transversus thoracis
Pericardium
M. transversus thoracis

PLATE X

PLATE X

Plate X is from the upper surface of a section through the upper third of the body of the seventh thoracic vertebra posteriorly and the lower part of the third intercostal space anteriorly. The plane of the section is 1.3 cm. anteriorly and 2.2 cm. posteriorly below that of the last section, making the anterior margin of the section .9 cm. lower than the posterior.

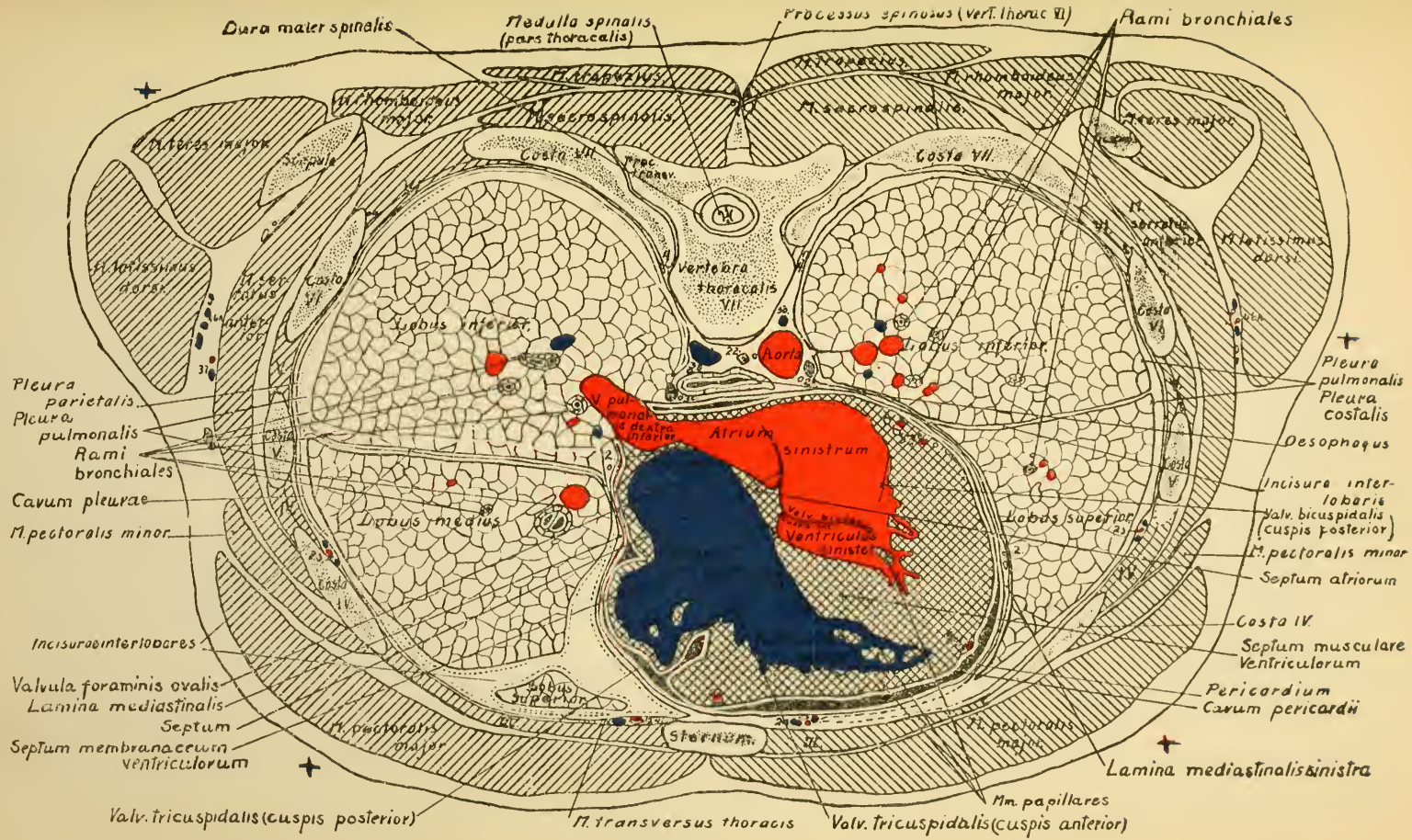
Dura mater spinalis
Medulla spinalis (pars thoracalis)
Processus spinosus (vert. thorac. VI)
Rami bronchiales
M. trapezius
M. rhomboideus major
M. sacrospinalis
M. teres major
Scapula
Costa VII
Proc. transv.
Vertebra thoracalis VII
M. latissimus dorsi
M. serratus anterior
Costa VI
Lobus inferior
Aorta
Lobus inferior
Pleura parietalis
Pleura pulmonalis
Rami bronchiales
Cavum pleurae
M. pectoralis minor
Costa V
Lobus medius
Atrium sinistrum
Ventriculus sinister
Lobus superior
Pleura pulmonalis
Pleura costalis
Oesophagus
Incisura interlobaris
Valv. bicuspidalis (cuspis posterior)
M. pectoralis minor
Septum atriorum
Costa IV
Septum musculare Ventriculorum
Pericardium
Cavum pericardii
Lamina mediastinalis sinistra
Incisurae interlobares
Valvula foraminis ovalis
Lamina mediastinalis
Septum
Septum membranaceum ventriculorum
Lobus superior
M. pectoralis major
Sternum
M. pectoralis major
Mm. papillares
Valv. tricuspidalis (cuspis posterior)
M. transversus thoracis
Valv. tricuspidalis (cuspis anterior)

PLATE XI

PLATE XI

Plate XI is from the upper surface of a section through the intervertebral disc (Fibrocartilago intervertebralis VII) between the seventh and eighth thoracic vertebrae posteriorly and through the fourth sternochondral articulations anteriorly. The plane of the section is 1.5 cm. anteriorly and 2.4 cm. posteriorly below that of the last section, so that it is horizontal.

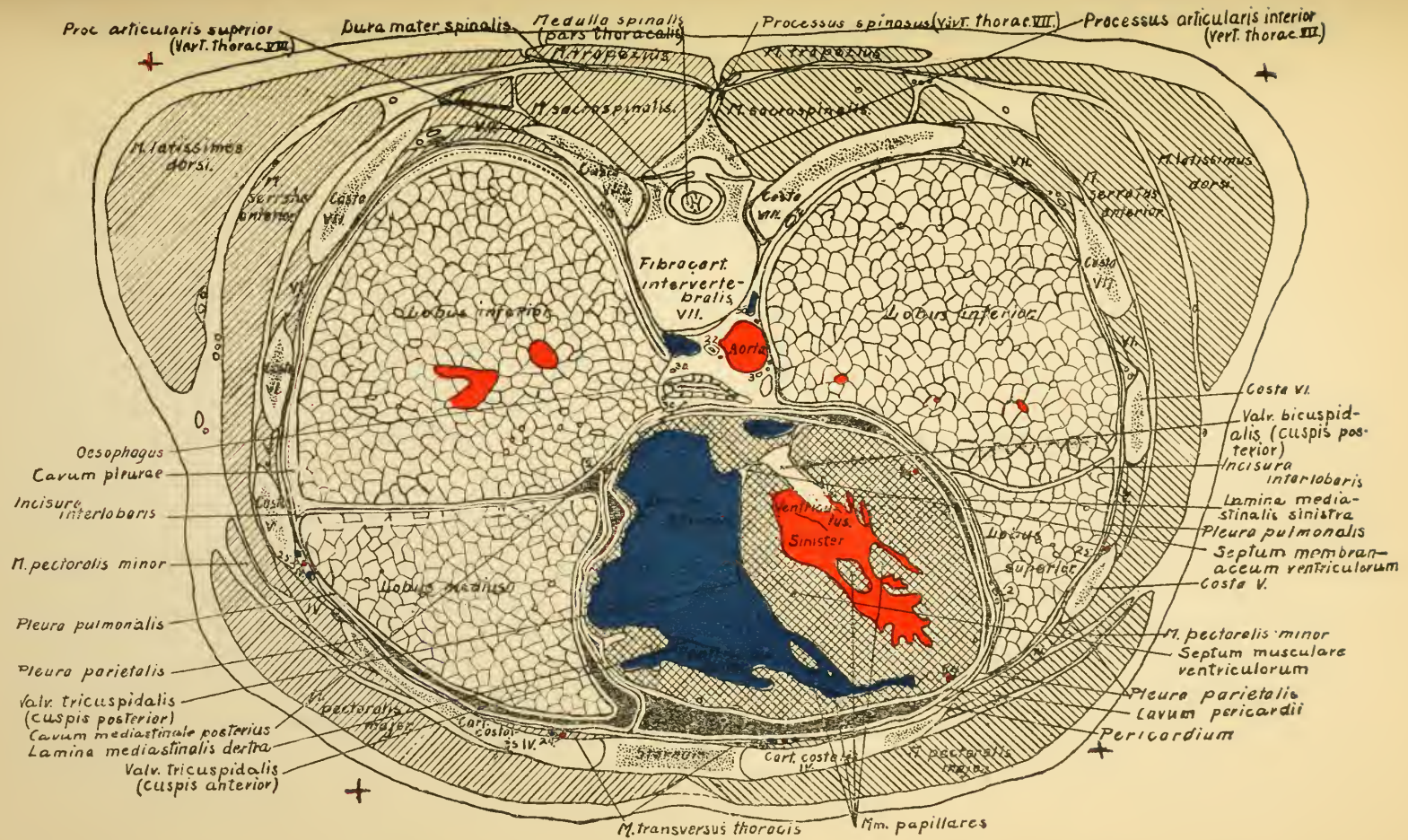
Proc. articularis superior (Vert. Thorac. VIII)
Dura mater spinalis
Medulla spinalis (pars thoracalis)
Processus spinosus (Vert. thorac. VIII)
Processus articularis inferior (Vert. thorac. VIII)
M. trapezius
M. latissimus dorsi
M. sacrospinalis
M. serratus anterior
Costa VII
Fibrocart. intervertebralis VII
Lobus inferior
Aorta
Oesophagus
Cavum pleurae
Incisura interloboris
M. pectoralis minor
Pleura pulmonalis
Pleura parietalis
Valv. tricuspidalis (cuspis posterior)
Cavum mediastinale posterius
Lamina mediastinalis dextra
Valv. tricuspidalis (cuspis anterior)
Lobus medius
Ventriculus Sinister
Lobus superior
Costa VI.
Valv. bicuspidalis (cuspis posterior)
Incisura interloboris
Lamina mediastinalis sinistra
Pleura pulmonalis
Septum membranaceum ventriculorum
Costa V.
M. pectoralis minor
Septum musculare ventriculorum
Pleura parietalis
Cavum pericardii
Pericardium
M. pectoralis major
Cart. costalis IV.
Sternum
M. transversus thoracis
Mm. papillares

PLATE XI.

PLATE XII

PLATE XII

Plate XII is from the upper surface of a section through the uppermost part of the disc between the eighth and ninth thoracic vertebrae posteriorly and the articulations of the fifth costal cartilages with the sternum anteriorly. The plane of the section is 2.5 cm. below that of the last section and is horizontal.

The vena cava inferior pierces the diaphragm and enters the inferior and posterior part of the right auricle (Atrium dextrum) near the upper surface of this section. What is labeled vena cava inferior in the plate is in reality the lowest part of the auricle into which the vein opens about .5 cm. below the surface of the section.

The right pleural cavity appears exaggerated in size in this figure, on account of the great width of the shallow space between the base of the lung and the superior surface of the diaphragm. A similar exaggeration is seen in the pericardial cavity.

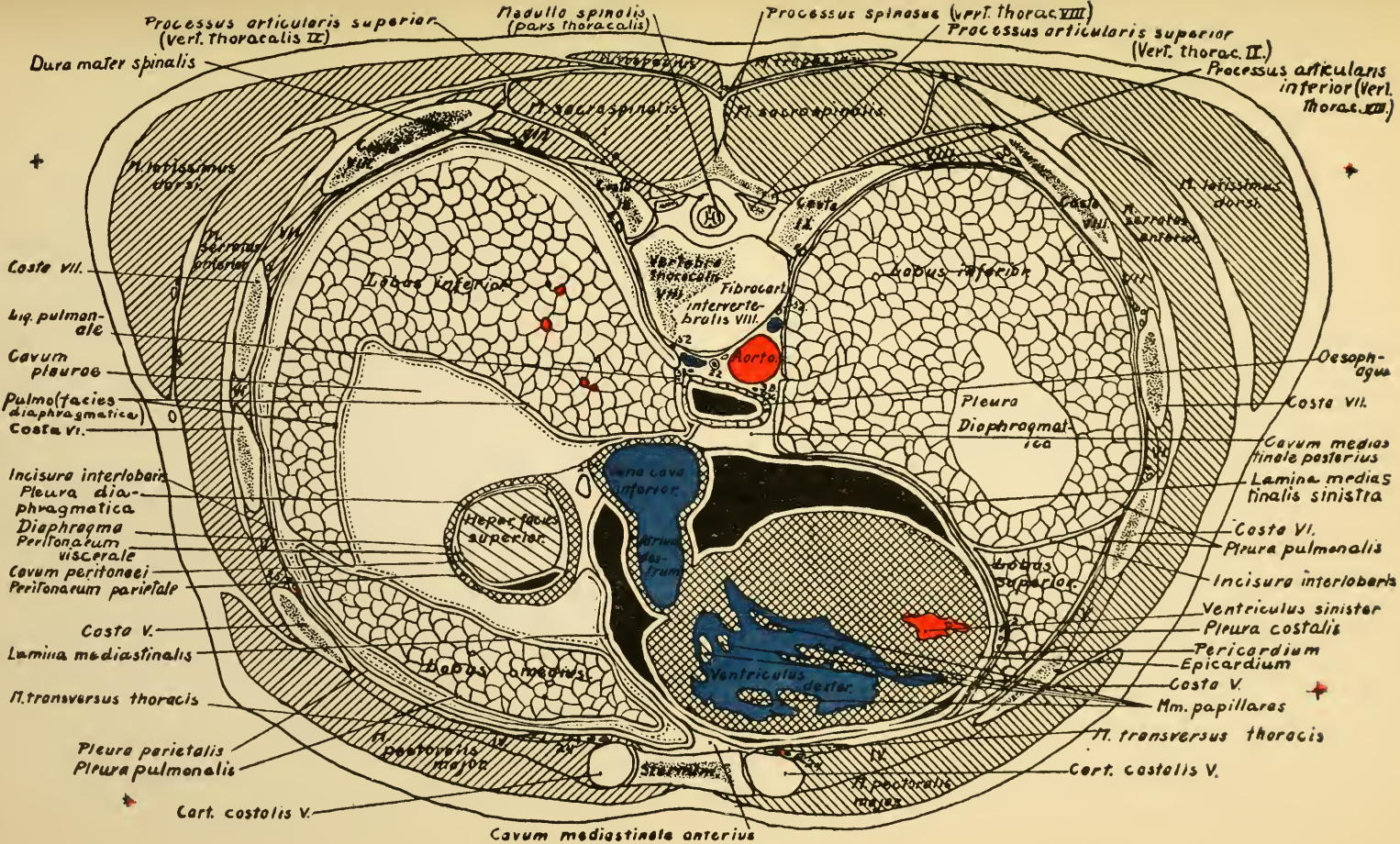
Processus articularis superior (Vert. thoracalis IX)
Medulla spinalis (pars thoracalis)
Processus spinosus (vert. thorac. VIII)
Processus articularis superior (Vert. thorac. II.)
Dura mater spinalis
Processus articularis inferior (Vert. thorac. XII.)
M. sacrospinalis
M. sacrospinalis
M. latissimus dorsi
M. latissimus dorsi
M. serratus anterior
M. serratus anterior
Costa VII.
Lobus inferior
Lobus inferior
Vertebra thoracalis VIII
Fibrocartilago interarticularis VIII.
Lig. pulmonale
Cavum pleurae
Pulmo (facies diaphragmatica)
Costa VI.
Aorta
Oesophagus
Pleura Diaphragmatica
Costa VII.
Cavum mediastinale posterius
Lamina mediastinalis sinistra
Incisura interlobaris
Pleura diaphragmatica
Diaphragma
Peritonaeum viscerale
Cavum peritonaei
Peritonaeum parietale
Vena cava inferior
Hepar facies superior
Atrium dextrum
Costa VI.
Pleura pulmonalis
Incisura interlobaris
Lobus superior
Ventriculus sinister
Pleura costalis
Pericardium
Epicardium
Costa V.
Mm. papillares
M. transversus thoracis
Cart. costalis V.
Costa V.
Lamina mediastinalis
Lobus anterius
Ventriculus dexter
M. transversus thoracis
Pleura parietalis
Pleura pulmonalis
M. pectoralis major
Sternum
M. pectoralis major
Cart. costalis V.
Cavum mediastinale anterius

PLATE XII.

PLATE XIII

PLATE XIII

Plate XIII is from the upper surface of a section through the intervertebral disc (Fibrocartilago intervertebralis IX) between the ninth and tenth thoracic vertebrae posteriorly and the sternoxiphoid articulation anteriorly. The plane of the section is 1.9 cm. anteriorly and 2.1 cm. posteriorly below that of the last section, and is .2 cm. lower behind than in front.

The lowest portion of the pericardial cavity appears as a shallow space separating the diaphragm from the fifth left costal cartilage. In reality this space is occupied by the tip of the apex of the heart, which by an oversight was omitted from the plate.

The oesophagus is turning to the left of the midplane preparatory to entering the stomach in this section. The upper pole of the spleen (Lien) comes nearly to the surface of the section between the posterior surface of the stomach and the diaphragm.

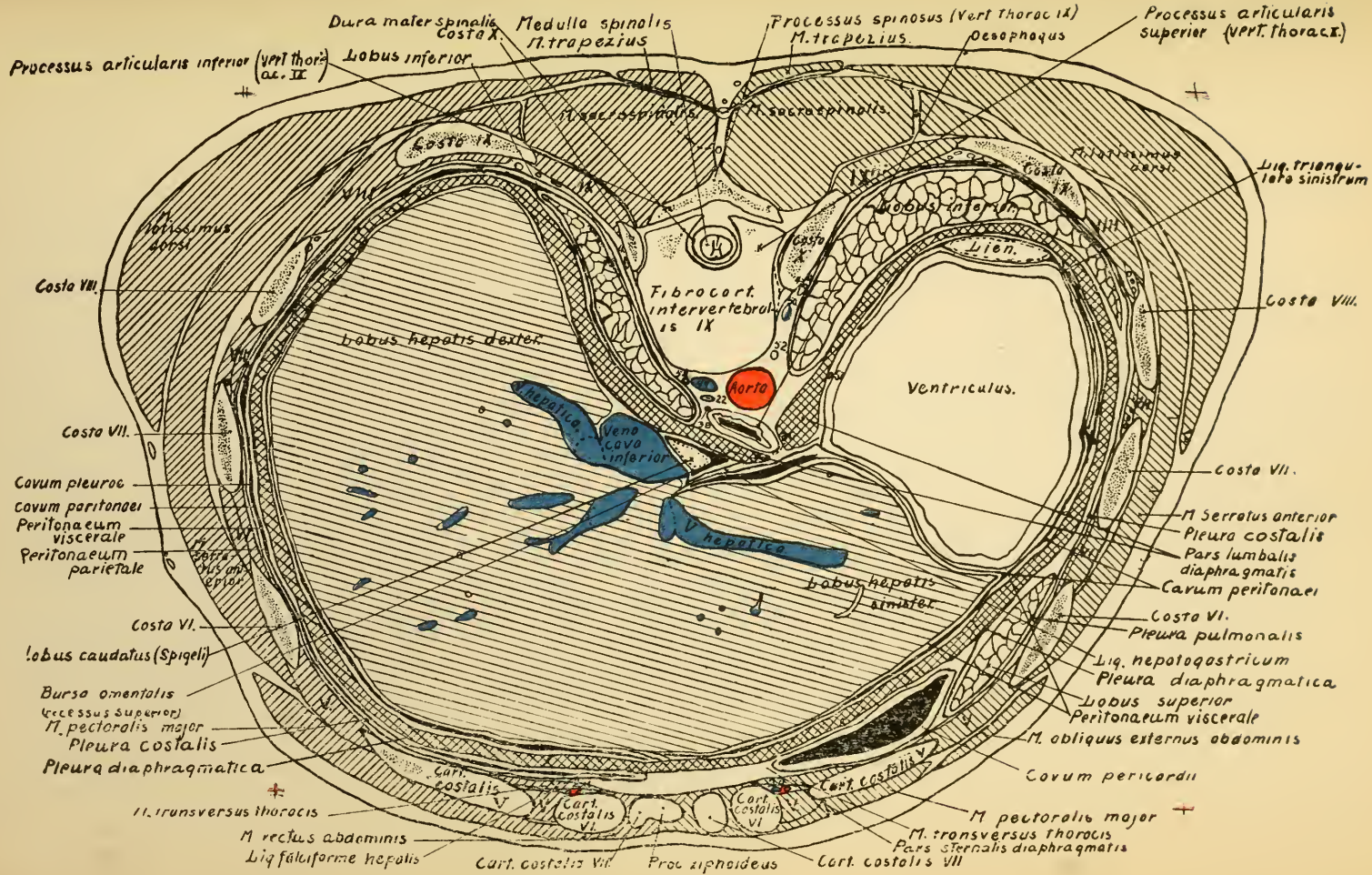
Dura mater spinalis
Costa X.
Medulla spinalis
M. trapezius
Processus spinosus (Vert thorac IX)
M. trapezius.
Oesophagus
Processus articularis superior (vert. thorac. X.)
Processus articularis inferior (vert thorac. IX)
Lobus inferior
M. sacrospinalis.
M. sacrospinalis.
Costa IX
Costa IX
Lig. triangulare sinistrum
Lobus inferior
Lien.
Costa VIII.
Costa VIII.
Fibrocart. intervertebralis IX
Lobus hepatis dexter.
Aorta
Ventriculus.
V. hepatica
Vena cava inferior
Costa VII.
Costa VII.
Cavum pleurae
Cavum peritonaei
Peritonaeum viscerale
Peritonaeum parietale
M. Serratus anterior
Pleura costalis
Pars lumbalis diaphragmatis
Cavum peritonaei
V. hepatica
Lobus hepatis sinister.
Costa VI.
Costa VI.
Pleura pulmonalis
Lobus caudatus (Spigeli)
Lig. hepatogastricum
Pleura diaphragmatica
Bursa omentalis (recessus superior)
Lobus superior
Peritonaeum viscerale
M. pectoralis major
Pleura costalis
M. obliquus externus abdominis
Pleura diaphragmatica
Cavum pericardii
Cart. costalis V
Cart. costalis V
Cart. costalis VI
Cart. costalis VI
M. transversus thoracis
M. pectoralis major
M. rectus abdominis
M. transversus thoracis
Pars sternalis diaphragmatis
Lig falciforme hepatis
Cart. costalis VII
Proc. ziphoideus
Cart. costalis VII

PLATE XIV

PLATE XIV

Plate XIV is from the upper surface of a section through the intervertebral disc (Fibrocartilago intervertebralis X) between the tenth and eleventh thoracic vertebrae posteriorly and the middle of the xiphoid process anteriorly. The plane of the section is 2.0 cm. anteriorly and 2.8 cm. posteriorly below that of the last section, so that it is 1 cm. lower posteriorly than anteriorly.

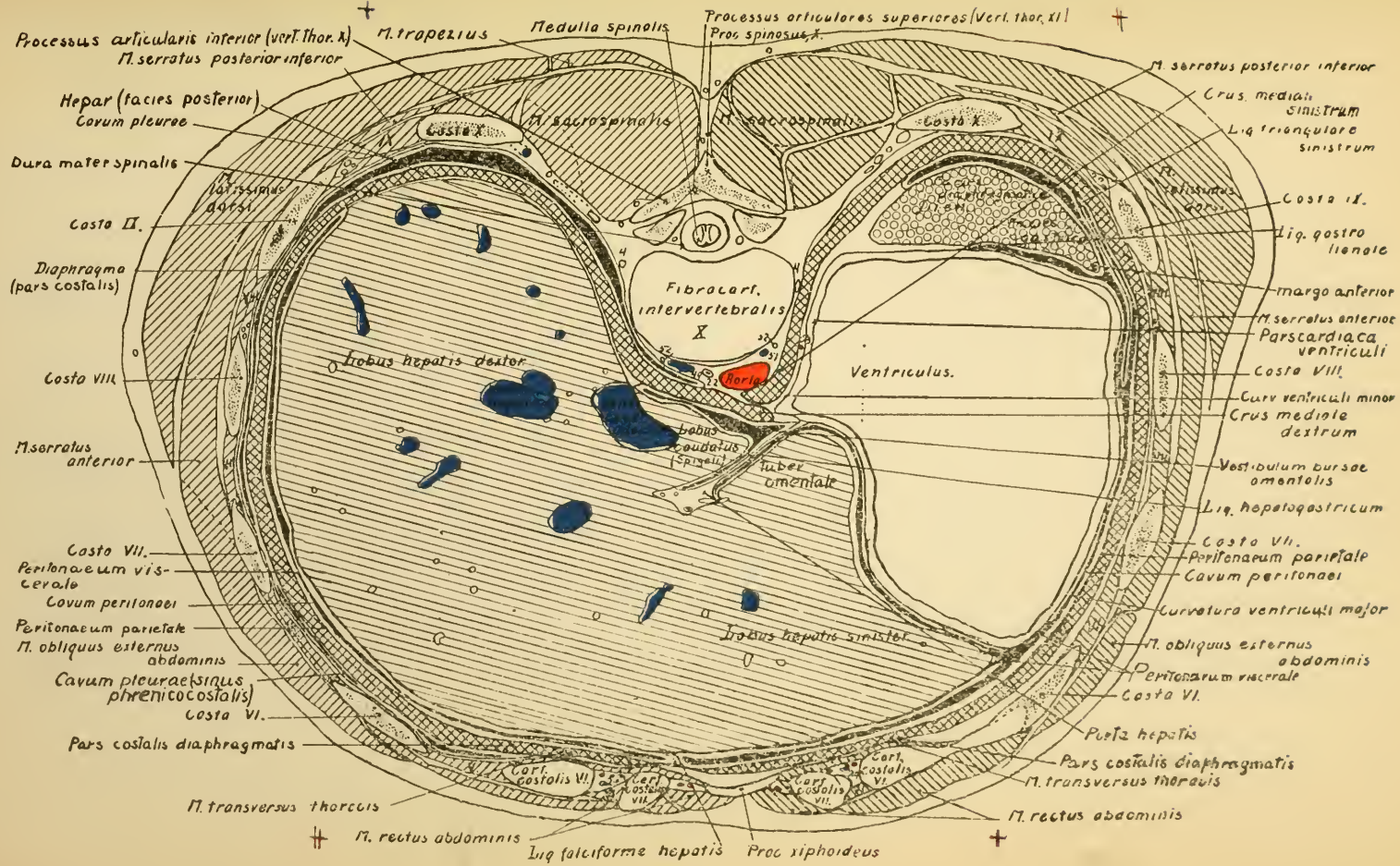
Processus articularis inferior (vert. thor. X)
M. serratus posterior inferior
Hepar (facies posterior)
Cavum pleurae
Dura mater spinalis
M. latissimus dorsi
Costa II.
Diaphragma (pars costalis)
Costa VIII.
M. serratus anterior
Costa VII.
Peritonaeum viscerale
Cavum peritonaei
Peritonaeum parietale
M. obliquus externus abdominis
Cavum pleurae (sinus phrenicocostalis)
Costa VI.
Pars costalis diaphragmatis
M. transversus thoracis
M. rectus abdominis
Lig. falciforme hepatis
Proc. xiphoideus
M. trapezius
Medulla spinalis
Processus articulares superiores (vert. thor. XI)
Proc. spinosus X.
M. sacrospinalis
Costa X.
Fibrocart. intervertebralis X
Lobus hepatis dexter
Aorta
Lobus caudatus (Spigeli)
Tuber omentale
Lobus hepatis sinister
Cart. costalis VII.
Cart. costalis VIII.
Cart. costalis VI.
M. serratus posterior inferior
Crus mediale sinistrum
Lig. triangulare sinistrum
Costa XI.
Lig. gastrolienale
Margo anterior
M. serratus anterior
Pars cardiaca ventriculi
Ventriculus.
Costa VIII.
Curv. ventriculi minor
Crus mediale dextrum
Vestibulum bursae omentalis
Lig. hepatogastricum
Costa VII.
Peritonaeum parietale
Cavum peritonaei
Curvatura ventriculi major
M. obliquus externus abdominis
Peritonaeum viscerale
Costa VI.
Porta hepatis
Pars costalis diaphragmatis
M. transversus thoracis
M. rectus abdominis

PLATE XIV.

PLATE XV

PLATE XV

Plate XV is from the upper surface of a section through the intervertebral disc (Fibrocartilago intervertebralis XI) between the eleventh and twelfth thoracic vertebrae posteriorly, and the tip of the xiphoid process anteriorly. The plane of the section is 2.7 cm. posteriorly and 3 cm. anteriorly below that of the last section. Its posterior margin is .7 cm. lower than its anterior.

The stomach and spleen are separated from each other by a recess of the lesser peritonaeal cavity (Recessus lienalis bursae omentalis). This recess of the lesser cavity is continuous slightly below the surface of the section with the vestibule of the lesser cavity by a passage way (sometimes called "Huschke's foramen") bounded by the lesser curvature of the stomach anteriorly, and the plica gastropancreatica posteriorly.

Processus articularis superior (Vert. thor. XII)
Costa XI.
Medulla spinalis
Processus spinosus (Vert. thor. XI)
Processus articularis superior (Vert. thor. XII)
M. serratus posterior inferior
M. serratus posterior inferior
M. sacrospinalis
M. sacrospinalis
Lig. triangulare sinistrum
Hilus lienis
B. omentalis (recessus lienalis)
Gl. suprarenalis
Costa IX.
Fibrocart. intervertebralis XI.
Lobus hepatis dexter
Lig. gastrolienale
Costa IX.
Crus sinistrum
M. serratus anterior
Crus dextrum
Costa VIII.
Curvatura ventriculi major
Diaphragma
Omentum majus
B. omentalis
Costa VII.
Vestibulum bursae omentalis
Lig. hepatogastricum
M. obliquus externus abdominis
Apex suprarenalis (gl. dextrae)
Costa VIII.
M. serratus anterior
V. portae
Porta hepatis
Diaphragma
Cavum pleurae
Cavum peritonaei
Costa VII
Peritonaeum viscerale
Peritonaeum parietale
M. obliquus externus abdominis
Incisura umbilicalis
Lig. teres hepatis
Lig. falciforme hepatis
M. transversus abdominis
Processus xiphoideus
Cavum peritonaei
M. transversus abdominis
Aorta
Vena cava inferior
Lobus caudatus (Spigeli)
Ventriculus (corpus)
Lobus hepatis sinister
Pars pylorica
Cart. costalis VII.
Cart. costalis VII.

PLATE XV.

PLATE XVI

PLATE XVI

Plate XVI is from the upper surface of a section through the lowermost portion of the twelfth thoracic vertebra posteriorly and the costal cartilages of the eighth ribs anteriorly. The section is 2.5 cm. anteriorly and 2 cm. posteriorly below the plane of the last section. The posterior margin is .2 cm. lower than the anterior.

The common bile duct (56) lies external to the portal vein and the hepatic artery. The cystic duct (55) is cut at its origin at the neck of the gall bladder (Collum vesicae felleae). The cystic and hepatic ducts unite in the lower part of the section above to form the common bile duct. The sections of the intestine are numbered consecutively, as they would be encountered in passing down the alimentary canal. The letter is the initial letter of the name of the part and the subscript denotes the number of the serial section. The letter I has been used to denote jejunum as well as ileum.

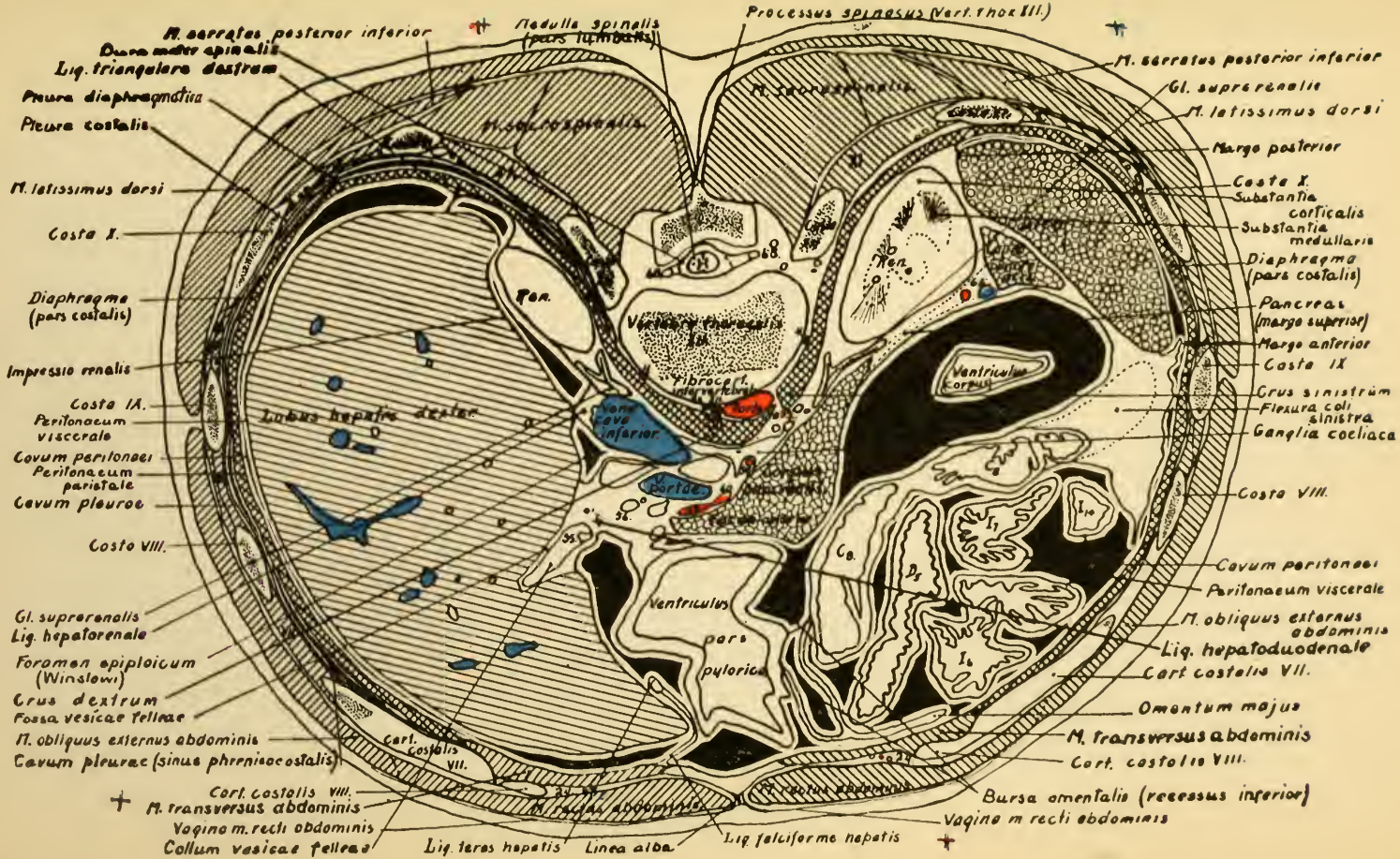
M. serratus posterior inferior
Dura mater spinalis
Lig. triangulare dextrum
Pleura diaphragmatica
Pleura costalis
M. latissimus dorsi
Costa X.
Diaphragma (pars costalis)
Impressio renalis
Costa IX.
Peritonaeum viscerale
Cavum peritonaei
Peritonaeum parietale
Cavum pleurae
Costa VIII.
Gl. suprarenalis
Lig. hepatorenale
Foramen epiploicum (Winslowi)
Crus dextrum
Fossa vesicae felleae
M. obliquus externus abdominis
Cavum pleurae (sinus phrenicocostalis)
Cart. costalis VIII.
M. transversus abdominis
Vagina m. recti abdominis
Collum vesicae felleae
Lig. teres hepatis
Linea alba
Lig. falciforme hepatis
Vagina m recti abdominis
Bursa omentalis (recessus inferior)
Cart. costalis VIII.
M. transversus abdominis
Omentum majus
Cart. costalis VII.
Lig. hepatoduodenale
M. obliquus externus abdominis
Cavum peritonaei
Peritonaeum viscerale
Costa VIII.
Ganglia coeliaca
Flexura coli sinistra
Crus sinistrum
Costa IX
Marge anterior
Pancreas (margo superior)
Diaphragma (pars costalis)
Substantia medullaris
Substantia corticalis
Costa X.
Margo posterior
M. latissimus dorsi
Gl. suprarenalis
M. serratus posterior inferior
Processus spinosus (Vert. thor. XII.)
Medulla spinalis (pars lumbalis)
M. sacrospinalis
Ren.
Lobus hepatis dexter
Vena cava inferior
Ventriculus pars pylorica
Ventriculus corpus
Cart. costalis VII.

PLATE XVII

PLATE XVII

Plate XVII is from a section through the lower third of the first lumbar vertebra. The plane of the section is 2.8 cm. anteriorly and 2.7 cm. posteriorly below that of Plate XVI so that the posterior margin is .1 cm. lower than the anterior.

The left renal vein empties into the vena cava inferior near the surface of the section. Its course is indicated in the plate. It receives the suprarenal vein (62) from above.

The lower part of the first portion of the duodenum (D_1) is attached to the posterior part of the stomach. The posterior of the two segments marked (D_1) continues downward as the descending duodenum. The last portion of the duodenum (D_4) lies to the left of the midline opposite the first portion.

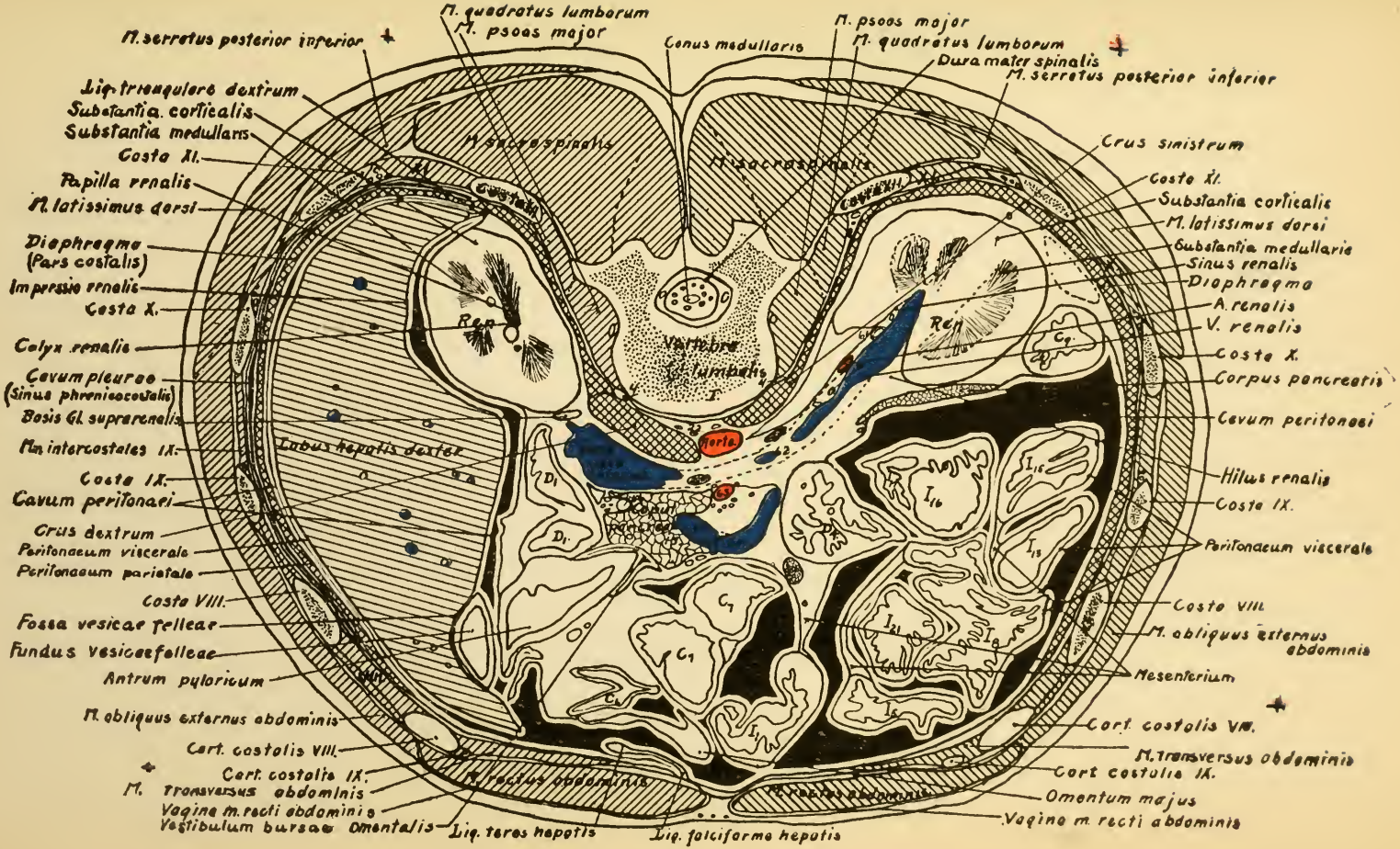
M. quadratus lumborum
M. psoas major
M. serratus posterior inferior
Lig. triangulare dextrum
Substantia corticalis
Substantia medullaris
Costa XI.
Papilla renalis
M. latissimus dorsi
Diaphragma (Pars costalis)
Impressio renalis
Costa X.
Calyx renalis
Cavum pleurae (Sinus phrenicocostalis)
Basis Gl. suprarenalis
Mm. intercostales IX.
Costa IX.
Cavum peritonaei
Crus dextrum
Peritonaeum viscerale
Peritonaeum parietale
Costa VIII.
Fossa vesicae felleae
Fundus vesicae felleae
Antrum pyloricum
M. obliquus externus abdominis
Cart. costalis VIII.
Cart. costalis IX.
M. transversus abdominis
Vagina m. recti abdominis
Vestibulum bursae omentalis
M. sacrospinalis
Ren
Vertebra L. lumbalis I
Aorta
Tubus hepatis dexter
Pancreas
Lig. teres hepatis
Lig. falciforme hepatis
M. rectus abdominis
Conus medullaris
Dura mater spinalis
Crus sinistrum
Substantia corticalis
Sinus renalis
Diaphragma
A. renalis
V. renalis
Corpus pancreatis
Cavum peritonaei
Hilus renalis
Mesenterium
Cart. costalis VII.
Omentum majus
Vagina m. recti abdominis

PLATE XVII.

PLATE XVIII

PLATE XVIII

Plate XVIII is from the upper surface of a section through the lower half of the body of the second lumbar vertebra. The plane of the section is 3.3 cm. anteriorly and 2.8 cm. posteriorly below that of the last section hence its anterior margin is .4 cm. lower than its posterior.

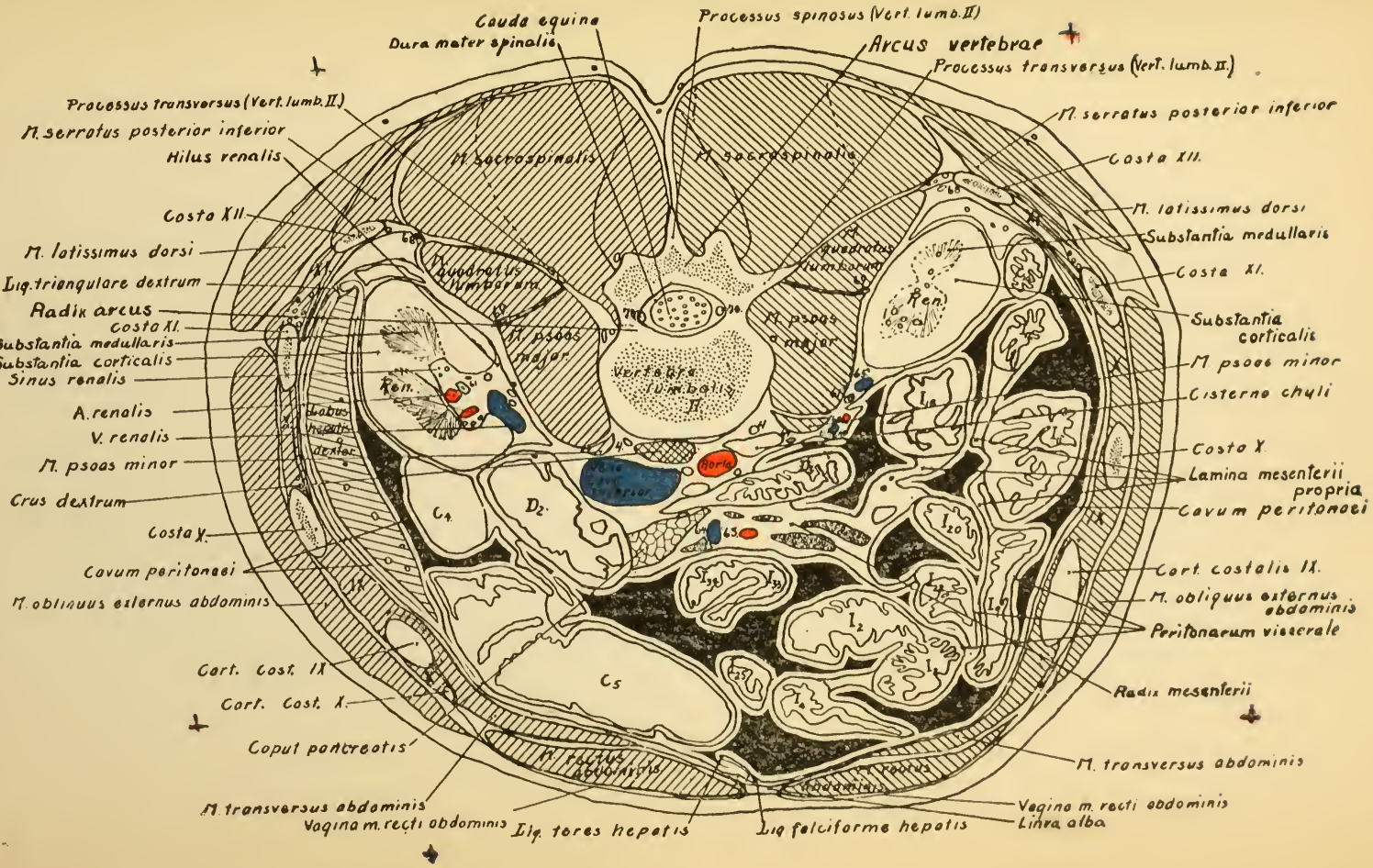
Cauda equina
Dura mater spinalis
Processus spinosus (Vert. lumb. II)
Arcus vertebrae
Processus transversus (Vert. lumb. II.)
Processus transversus (Vert. lumb. II.)
M. serratus posterior inferior
M. serratus posterior inferior
Hilus renalis
M. sacrospinalis
M. sacrospinalis
Costa XII.
Costa XII
M. latissimus dorsi
M. latissimus dorsi
Substantia medullaris
Lig. triangulare dextrum
M. quadratus lumborum
Costa XI.
Radix arcus
Costa XI.
M. psoas major
M. psoas major
Substantia medullaris
Substantia corticalis
Ren.
Ren.
Substantia corticalis
Sinus renalis
M. psoas minor
Vertebra lumbalis II.
Cisterna chyli
A. renalis
Lobus hepatis dexter
V. renalis
Aorta
Costa X.
M. psoas minor
Lamina mesenterii propria
Crus dextrum
Cavum peritonaei
Costa X.
Cort. costalis IX.
Cavum peritonaei
M. obliquus externus abdominis
M. obliquus externus abdominis
Peritonaeum viscerale
Cort. Cost. IX.
Cort. Cost. X.
Radix mesenterii
Caput pancreatis
M. rectus abdominis
M. transversus abdominis
M. transversus abdominis
Vagina m. recti abdominis
Lig. teres hepatis
Lig falciforme hepatis
Vagina m. recti abdominis
Linea alba

PLATE XVIII.

PLATE XIX

PLATE XIX

Plate XIX is from the upper surface of a section through the lower third of the third lumbar vertebra. The plane of the section is 3.7 cm. anteriorly and 3.8 cm. posteriorly below that of the last section, so that the anterior margin is .3 cm. below the posterior.

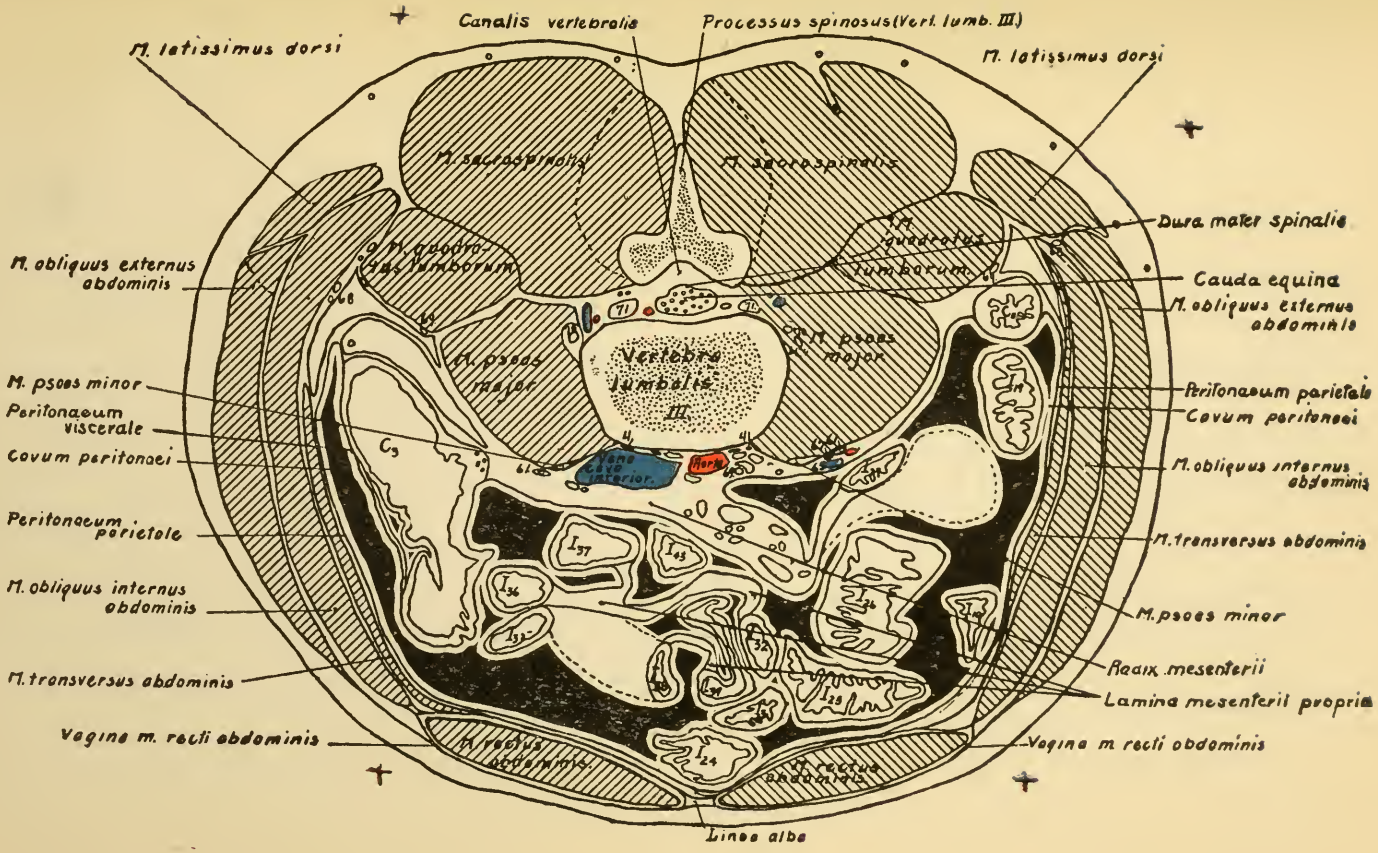
Canalis vertebralis
Processus spinosus (Vert. lumb. III)
M. latissimus dorsi
M. latissimus dorsi
M. sacrospinalis
M. sacrospinalis
Dura mater spinalis
M. quadratus lumborum
M. quadratus lumborum
Cauda equina
M. obliquus externus abdominis
M. obliquus externus abdominis
M. psoas major
M. psoas major
Vertebra lumbalis III
M. psoas minor
Peritonaeum parietale
Peritonaeum viscerale
Cavum peritonaei
Cavum peritonaei
M. obliquus internus abdominis
Vena cava interior
Aorta
Peritonaeum parietale
M. transversus abdominis
M. obliquus internus abdominis
M. psoas minor
Radix mesenterii
M. transversus abdominis
Lamina mesenterii propria
Vagina m. recti abdominis
Vagina m. recti abdominis
M. rectus abdominis
M. rectus abdominis
Linea alba

PLATE XIX.

PLATE XX

PLATE XX

Plate XX is from the upper surface of a section through the middle of the body of the fourth lumbar vertebra. The plane of the section is 2.8 cm. anteriorly and 3.1 cm. posteriorly below that of the last section and is horizontal. It passes just above the highest point of the crest of the ilium.

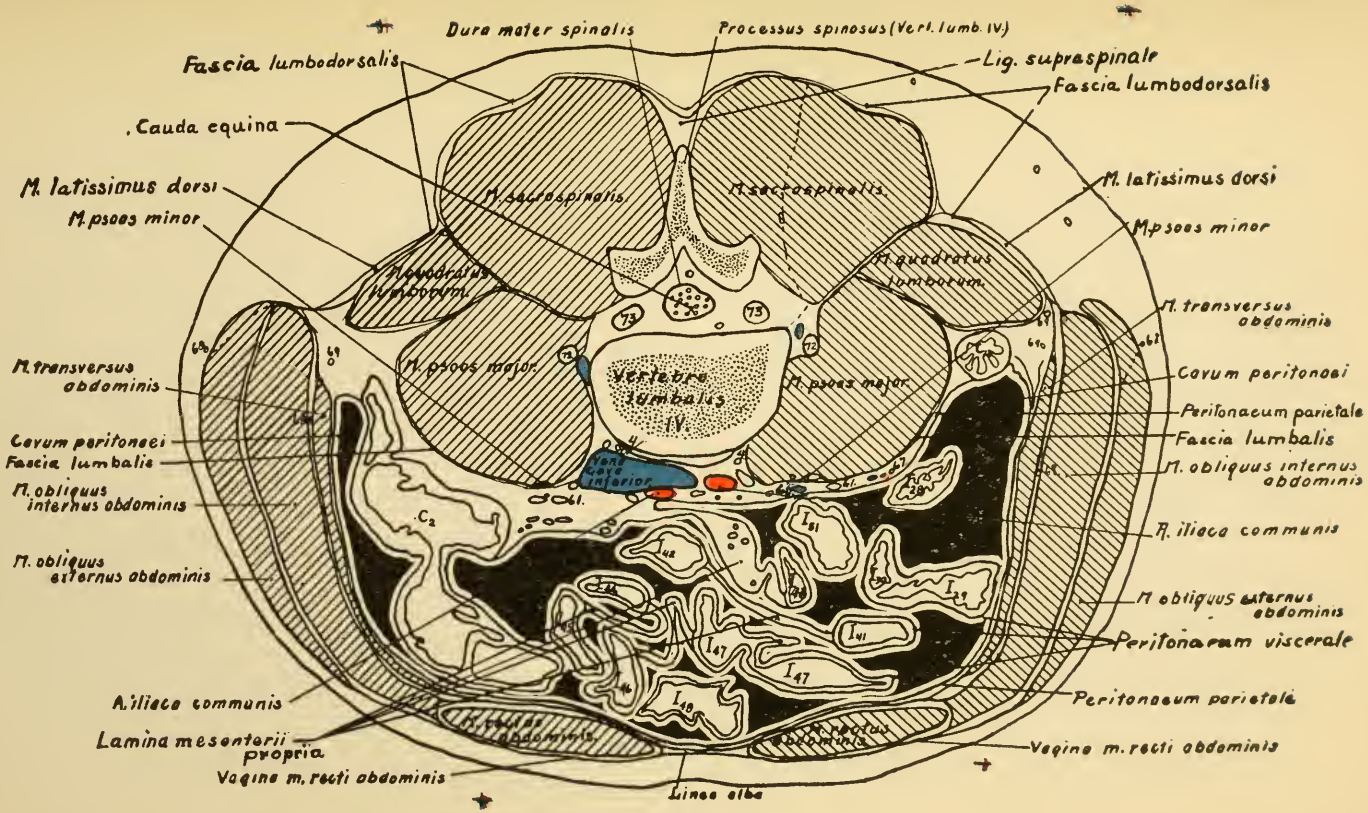
Dura mater spinalis
Processus spinosus (Vert. lumb. IV.)
Fascia lumbodorsalis
Lig. supraspinale
Fascia lumbodorsalis
Cauda equina
M. latissimus dorsi
M. sacrospinalis
M. sacrospinalis
M. latissimus dorsi
M. psoas minor
M. psoas minor
M. quadratus lumborum
M. quadratus lumborum
M. transversus abdominis
M. psoas major
Vertebra lumbalis IV
M. psoas major
Cavum peritonaei
M. transversus abdominis
Peritonaeum parietale
Cavum peritonaei
Fascia lumbalis
Fascia lumbalis
M. obliquus internus abdominis
M. obliquus internus abdominis
A. iliaca communis
M. obliquus externus abdominis
M. obliquus externus abdominis
Peritonaeum viscerale
A. iliaca communis
Peritonaeum parietale
Lamina mesenterii propria
M. rectus abdominis
Vagina m. recti abdominis
Vagina m. recti abdominis
Linea alba

PLATE XX.

PLATE XXI

PLATE XXI

Plate XXI is from the upper surface of a section through the lowermost part of the fifth lumbar vertebra. The plane of the section is 4.3 cm. anteriorly and 3 cm. posteriorly below that of the last section. Its anterior margin is 1.3 cm. lower than its posterior.

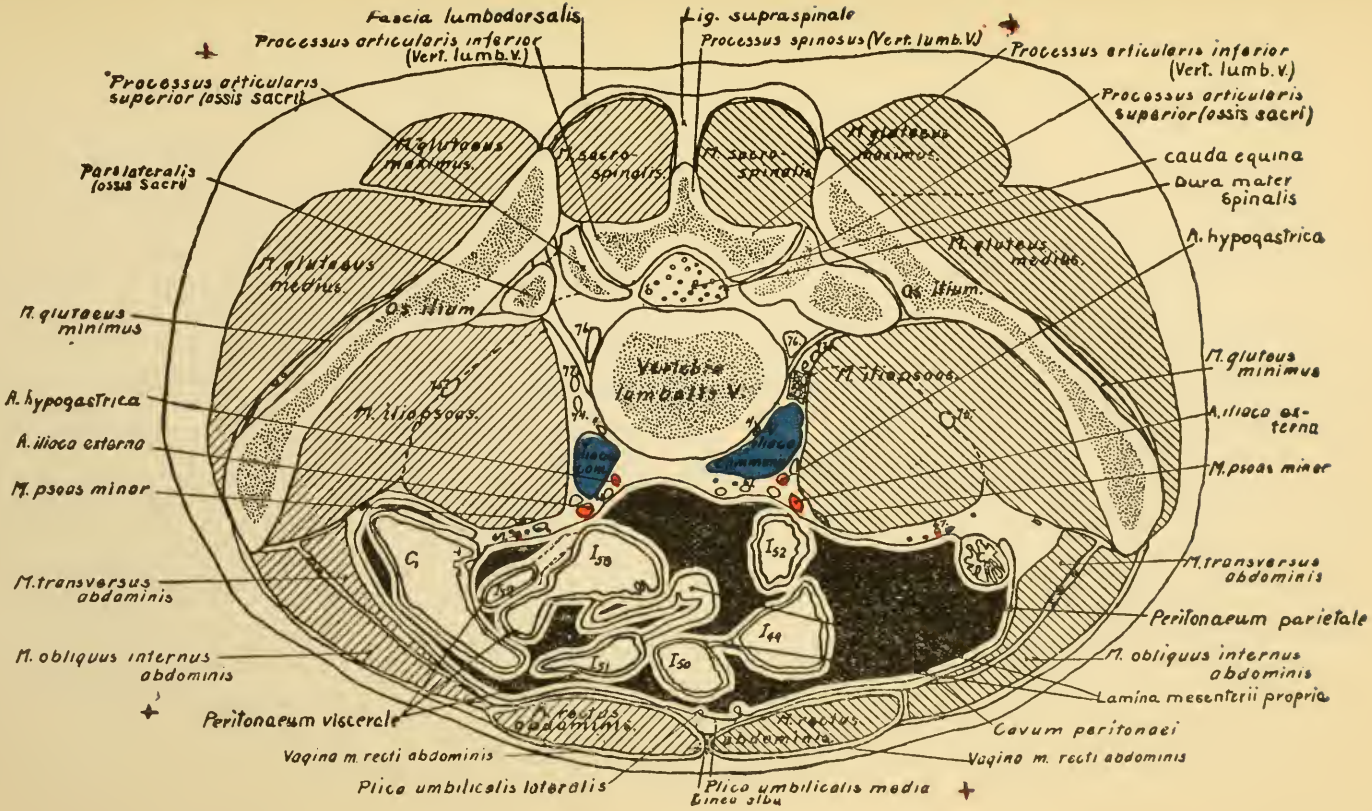
Fascia lumbodorsalis
Lig. supraspinale
Processus articularis inferior (Vert. lumb. V.)
Processus spinosus (Vert. lumb. V.)
Processus articularis inferior (Vert. lumb. V.)
Processus articularis superior (ossis sacri)
Processus articularis superior (ossis sacri)
M. glutaeus maximus.
M. sacro-spinalis.
M. spino-spinalis
M. glutaeus maximus.
Pars lateralis (ossis Sacri)
cauda equina
Dura mater spinalis
A. hypogastrica
M. glutaeus medius.
M. glutaeus medius.
Os ilium.
Os ilium.
M. glutaeus minimus
M. glutaeus minimus
Vertebra lumbalis V.
M. iliopsoas.
M. iliopsoas.
A. hypogastrica
A. iliaca externa
A. iliaca externa
M. psoas minor
M. psoas minor
M. transversus abdominis
M. transversus abdominis
Peritonaeum parietale
M. obliquus internus abdominis
M. obliquus internus abdominis
Lamina mesenterii propria
Peritonaeum viscerale
M. rectus abdominis.
M. rectus abdominis.
Cavum peritonaei
Vagina m. recti abdominis
Vagina m. recti abdominis
Plica umbilicalis lateralis
Plica umbilicalis media
Linea alba

PLATE XXI.

PLATE XXII

PLATE XXII

Plate XXII is from the upper surface of a section through the middle of the sacrum. The plane of the section is 4 cm. anteriorly, and 3.1 cm. posteriorly below that of the last section, so that the anterior margin is 2.2 cm. lower than the posterior.

The left plica umbilicalis lateralis extends across the corner of the peritonaeal cavity in the section cutting off a small pocket as indicated by the dotted line.

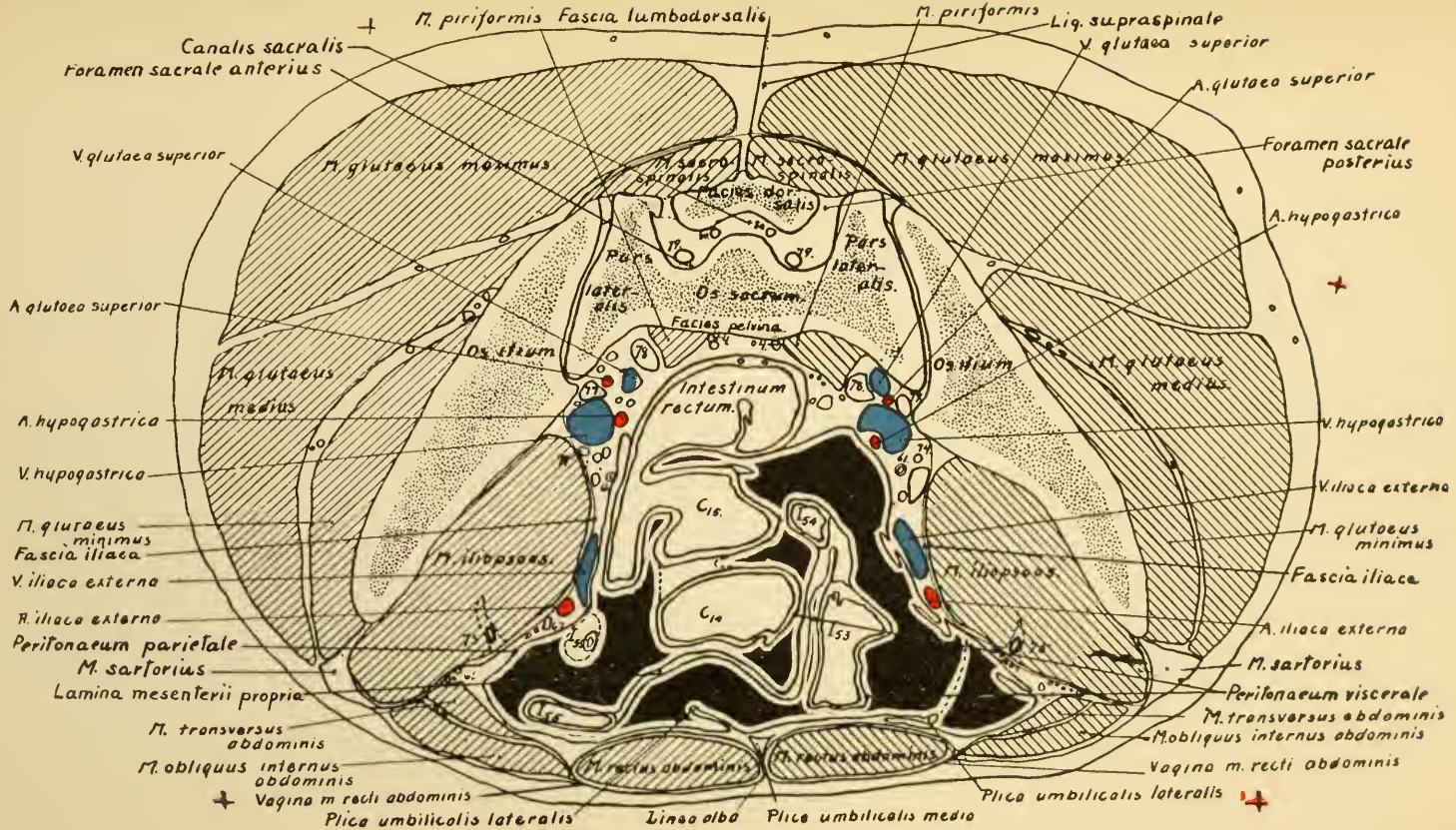
M. piriformis
Fascia lumbodorsalis
M. piriformis
Lig. supraspinale
Canalis sacralis
Foramen sacrale anterius
V. glutaea superior
A. glutaea superior
V. glutaea superior
M. glutaeus maximus
M. sacro-spinalis
M. sacro-spinalis
M. glutaeus maximus
Foramen sacrale posterius
Facies dorsalis
A. hypogastrica
Pars lateralis
Pars lateralis
Os sacrum
A. glutaea superior
Facies pelvina
Os ilium
Os ilium
M. glutaeus medius
M. glutaeus medius
Intestinum rectum
A. hypogastrica
V. hypogastrica
V. hypogastrica
V. iliaca externa
M. glutaeus minimus
Fascia iliaca
M. glutaeus minimus
Fascia iliaca
M. iliopsoas
M. iliopsoas
V. iliaca externa
A. iliaca externa
A. iliaca externa
Peritonaeum parietale
M. sartorius
M. sartorius
Lamina mesenterii propria
Peritonaeum viscerale
M. transversus abdominis
M. transversus abdominis
M. obliquus internus abdominis
M. obliquus internus abdominis
M. rectus abdominis
M. rectus abdominis
Vagina m. recti abdominis
Vagina m recti abdominis
Plica umbilicalis lateralis
Plica umbilicalis lateralis
Linea alba
Plica umbilicalis medio

PLATE XXII.

PLATE XXIII

PLATE XXIII

Plate XXIII is from the upper surface of a section through the first coccygeal vertebra posteriorly and the acetabular cavities of the ilia laterally. The plane of the section is 3.8 cm. anteriorly and 4.2 cm. posteriorly below that of the last section. The anterior margin is 1.8 cm. lower than the posterior.

The right plica umbilicalis lateralis stretches across the corner of the cavity cutting off a pocket like the one indicated on left side of section XXII. These two spaces are conical in form, about 4 cm. deep and closed everywhere except at the top.

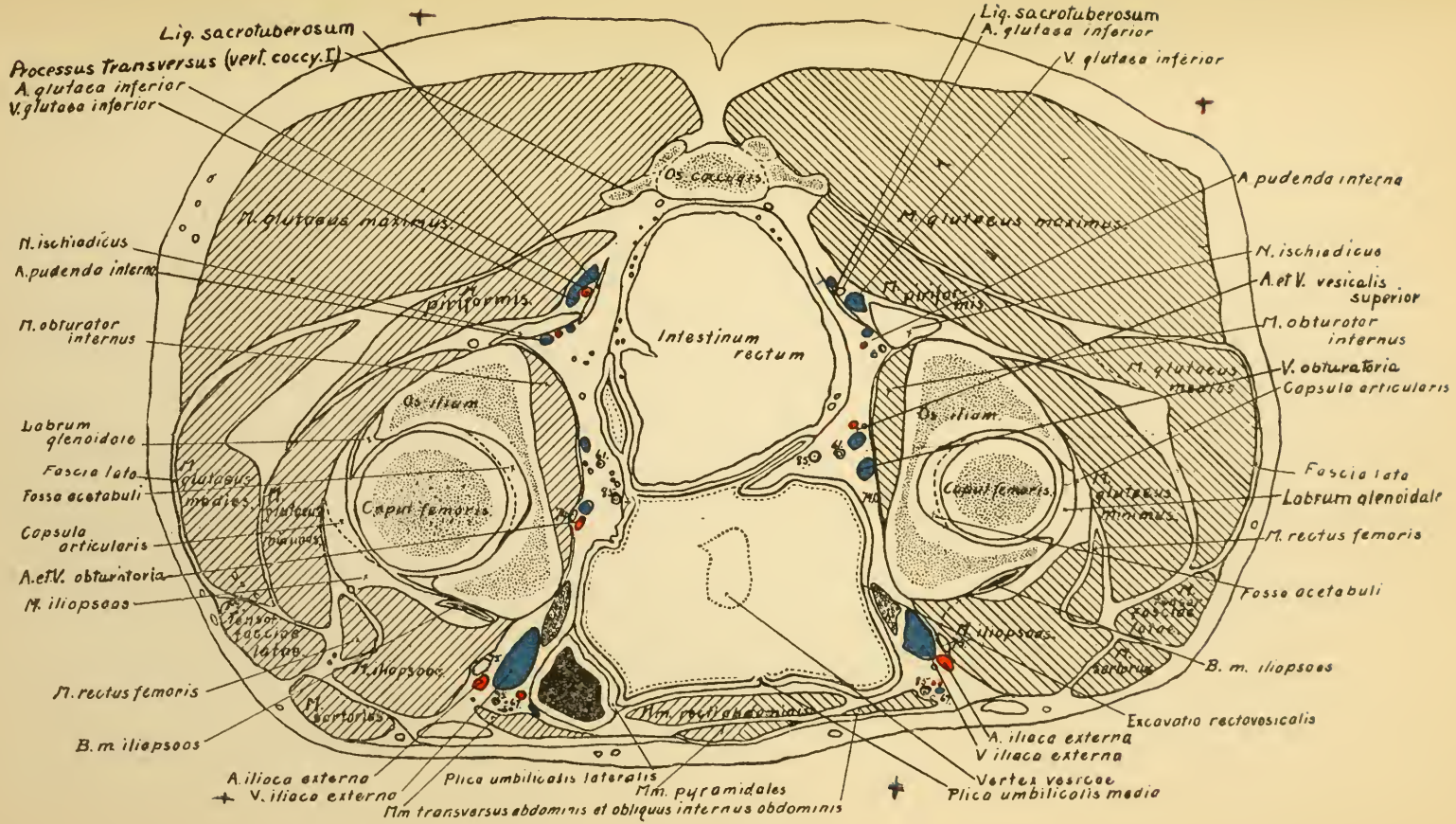
Lig. sacrotuberosum
Processus transversus (vert. coccy. I)
A. glutaea inferior
V. glutaea inferior
Os coccygis
M. glutaeus maximus
N. ischiadicus
A. pudenda interna
M. piriformis
M. obturator internus
Intestinum rectum
Os ilium
Labrum glenoidale
Fascia lata
M. glutaeus medius
Fossa acetabuli
Caput femoris
M. glutaeus minimus
Capsula articularis
A. et V. obturatoria
M. iliopsoas
M. tensor fasciae latae
M. rectus femoris
M. sartorius
B. m. iliopsoas
A. iliaca externa
V. iliaca externa
Plica umbilicalis lateralis
Mm. pyramidales
Mm transversus abdominis et obliquus internus abdominis
Mm. recti abdominis
Vertex vesicae
Plica umbilicalis media
Excavatio rectovesicalis
A. et V. vesicalis superior

PLATE XXIII.

PLATE XXIV

PLATE XXIV

Plate XXIV is from a section through the tip of the coccyx posteriorly, the middle of the body of the os pubis anteriorly and the superior rami of the ischia. The plane of the section is 4.3 cm. anteriorly and 4.5 cm. posteriorly below that of section XXIII so that the anterior margin is 1.3 cm. below the posterior.

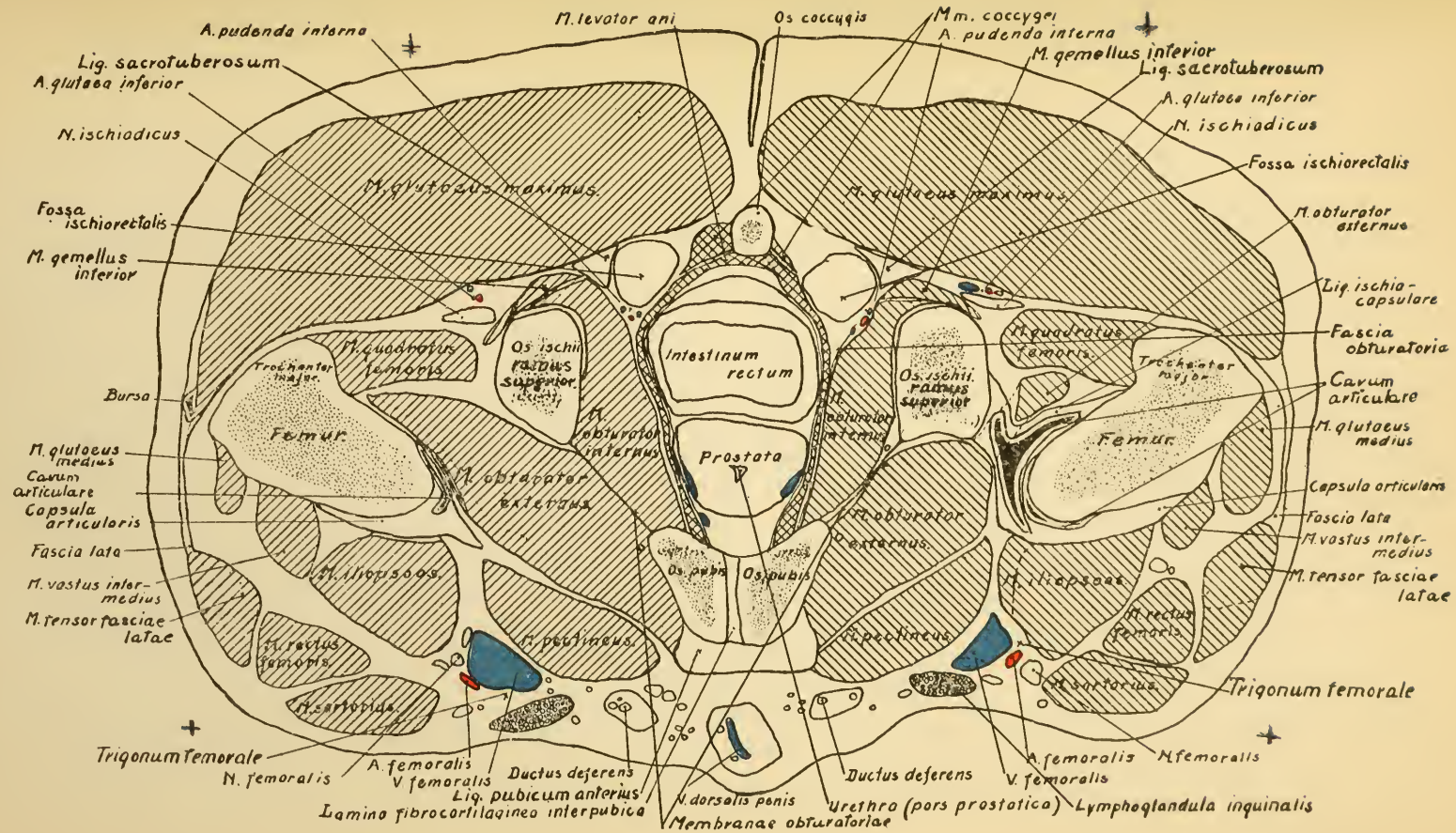
A. pudenda interna
Lig. sacrotuberosum
A. glutaea inferior
N. ischiadicus
Fossa ischiorectalis
M. gemellus inferior
M. levator ani
Os coccygis
Mm. coccygei
A. pudenda interna
M. gemellus inferior
Lig. sacrotuberosum
A. glutaea inferior
N. ischiadicus
Fossa ischiorectalis
M. obturator externus
Lig. ischio-capsulare
Fascia obturatoria
Carum articulare
M. glutaeus medius
Capsula articularis
Fascia lata
M. vastus intermedius
M. tensor fasciae latae
M. glutaeus maximus
M. glutaeus maximus
M. quadratus femoris
Os ischii, radius superior
Intestinum rectum
M. obturator internus
Prostata
M. obturator externus
M. iliopsoas
M. pectineus
M. rectus femoris
M. sartorius
Trochanter major
Femur
Bursa
M. glutaeus medius
Carum articulare
Capsula articularis
Fascia lata
M. vastus intermedius
M. tensor fasciae latae
M. quadratus femoris
Os ischii, radius superior
M. obturator internus
M. obturator externus
M. iliopsoas
M. pectineus
M. rectus femoris
M. sartorius
Os pubis
Os pubis
Trochanter major
Femur
Capsula articularis
Fascia lata
M. vastus intermedius
M. tensor fasciae latae
Trigonum femorale
Trigonum femorale
N. femoralis
A. femoralis
V. femoralis
Ductus deferens
Lig. pubicum anterius
Lamina fibrocartilaginea interpubica
N. dorsalis penis
Membranae obturatoriae
Urethra (pars prostatica)
Ductus deferens
A. femoralis
V. femoralis
N. femoralis
Lymphoglandula inguinalis

PLATE XXV

PLATE XXV

Plate XXV is from a section through the ischial tuberosities and the lesser trochanters of the femurs. The section is 4.3 cm. anteriorly and 5.4 cm. posteriorly below the last section. The anterior margin is .2 cm. below the posterior. This is about 4.5 cm. below the tip of the coccyx and 2.3 cm. below the inferior margin of the symphysis pubis.

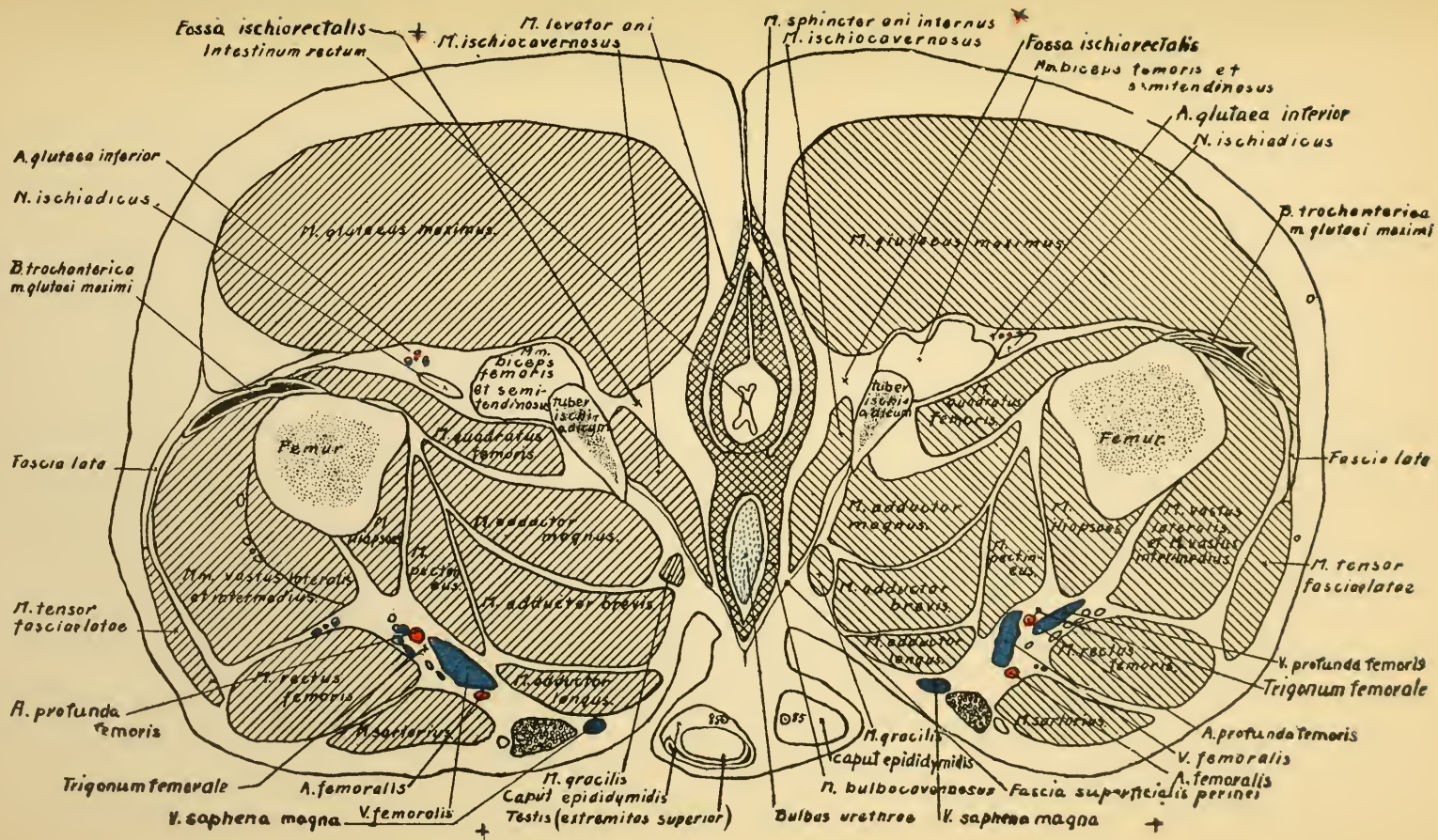
Fossa ischiorectalis
Intestinum rectum
M. levator ani
M. ischiocavernosus
M. sphincter ani internus
M. ischiocavernosus
Fossa ischiorectalis
Mm. biceps femoris et semitendinosus
A. glutaea inferior
N. ischiadicus
A. glutaea inferior
N. ischiadicus
M. glutaeus maximus
M. glutaeus maximus
B. trochanterica m. glutaei maximi
B. trochanterica m. glutaei maximi
Mm. biceps femoris et semitendinosus
Tuber ischiadicum
Tuber ischiadicum
M. quadratus femoris
M. quadratus femoris
Femur
Femur
Fascia lata
Fascia lata
M. adductor magnus
M. adductor magnus
M. vastus lateralis et intermedius
M. vastus lateralis et intermedius
M. tensor fasciae latae
M. tensor fasciae latae
M. adductor brevis
M. adductor brevis
M. adductor longus
M. adductor longus
M. rectus femoris
M. rectus femoris
V. profunda femoris
Trigonum femorale
A. profunda femoris
A. profunda femoris
M. sartorius
M. sartorius
V. femoralis
A. femoralis
Trigonum femorale
A. femoralis
M. gracilis
Caput epididymidis
Testis (extremitas superior)
M. gracilis
Caput epididymidis
N. bulbocavernosus
Fascia superficialis perinei
V. saphena magna
V. femoralis
Bulbus urethrae
V. saphena magna

PLATE XXV.

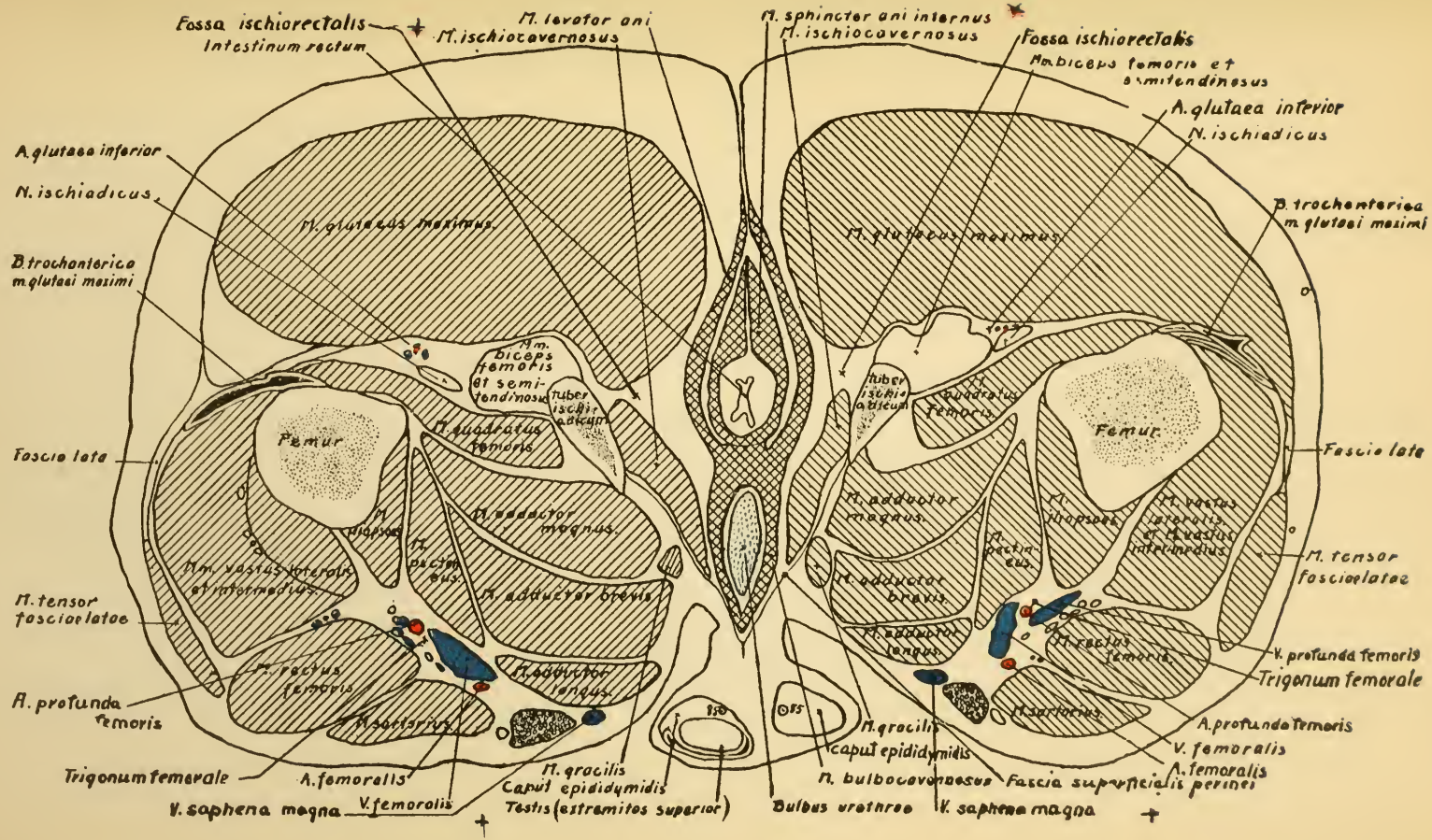
Fossa ischiorectalis
Intestinum rectum
M. levator ani
M. ischiocavernosus
M. sphincter ani internus
M. ischiocavernosus
Fossa ischiorectalis
Mm. biceps femoris et semitendinosus
A. glutaea inferior
N. ischiadicus
A. glutaea inferior
N. ischiadicus
B. trochanterica m. glutaei maximi
B. trochanterica m. glutaei maximi
M. glutaeus maximus
M. glutaeus maximus
Mm. biceps femoris et semitendinosus
tuber ischiadicum
M. quadratus femoris
Femur
Femur
Fascia lata
Fascia lata
M. adductor magnus
M. adductor brevis
M. adductor longus
M. pectineus
M. iliopsoas
M. vastus lateralis et M. vastus intermedius
M. tensor fasciae latae
M. tensor fasciae latae
M. rectus femoris
M. sartorius
M. rectus femoris
M. sartorius
A. profunda femoris
A. profunda femoris
V. profunda femoris
Trigonum femorale
Trigonum femorale
A. femoralis
V. femoralis
V. saphena magna
M. gracilis
Caput epididymidis
Testis (extremitas superior)
M. gracilis
caput epididymidis
M. bulbocavernosus
Bulbus urethrae
V. saphena magna
Fascia superficialis perinei
A. femoralis
V. femoralis
A. profunda femoris

PLATE XXV.

PLATE XXVI

PLATE XXVI

Plate XXVI is from a photograph of the anterior surface of the trunk, reconstructed by piling up the sections in their proper order, and is reduced to about one-fourth life size.

II.
III.
IV.
V.
VI.
VII.
VIII.
IX.
X.
XI.
XII.
XIII.
XIV.
XV.
XVI.
XVII.
XVIII.
XIX.
XX.
XXI.
XXII.
XXIII.
XXIV.
XXV.

PLATE XXVII

PLATE XXVII

Plate XXVII is from a photograph of the posterior surface of the trunk, shown in Plate XXVI and reduced in the same proportion.

The photographs were taken, in order to show the exact position of each section and its relations to the various landmarks of the body.

The number on each section corresponds to the number of the plate showing the upper surface of that section.

I.
II.
III.
IV.
V.
VI.
VII.
VIII.
IX.
X.
XI.
XII.
XIII.
XIV.
XV.
XVI.
XVII.
XVIII.
XIX.
XX.
XXI.
XXII.
XXIII.
XXIV.
XXV.

PLATE XXVII.

PLATE XXVIII

Plate XXVIII represents a projection of the various internal organs upon the anterior surface of the body reduced to one-half life size. The body outline was obtained by enlarging to life size, with a pantograph, the photographs used in making Plates XXVI and XXVII. The errors of proportion produced by the photographic lens were corrected by measurements of the body at the surface of each section. The section lines seen in Plate XXVI are represented in this plate by the horizontal black lines which run across the body. The exact position of these lines was obtained by placing the sections one upon the other in their proper position as was done to take the photographs shown in Plates XXVI and XXVII. A meter stick was then placed perpendicularly, parallel to the anterior midline of the body and the position of the upper surface of each section was measured by running a straight edge horizontally outward from the section to the meter stick.

The vertical line marked OO in this plate and in Plate XXIX is the midline of the body. In the anterior projection it connects the anterior ends of the midlines of the sections. In the posterior projection it connects the posterior ends of these same midlines.

The various organs are outlined in broken lines of sufficiently different character so that each organ may be traced without any difficulty. (These lines are explained on the plates.

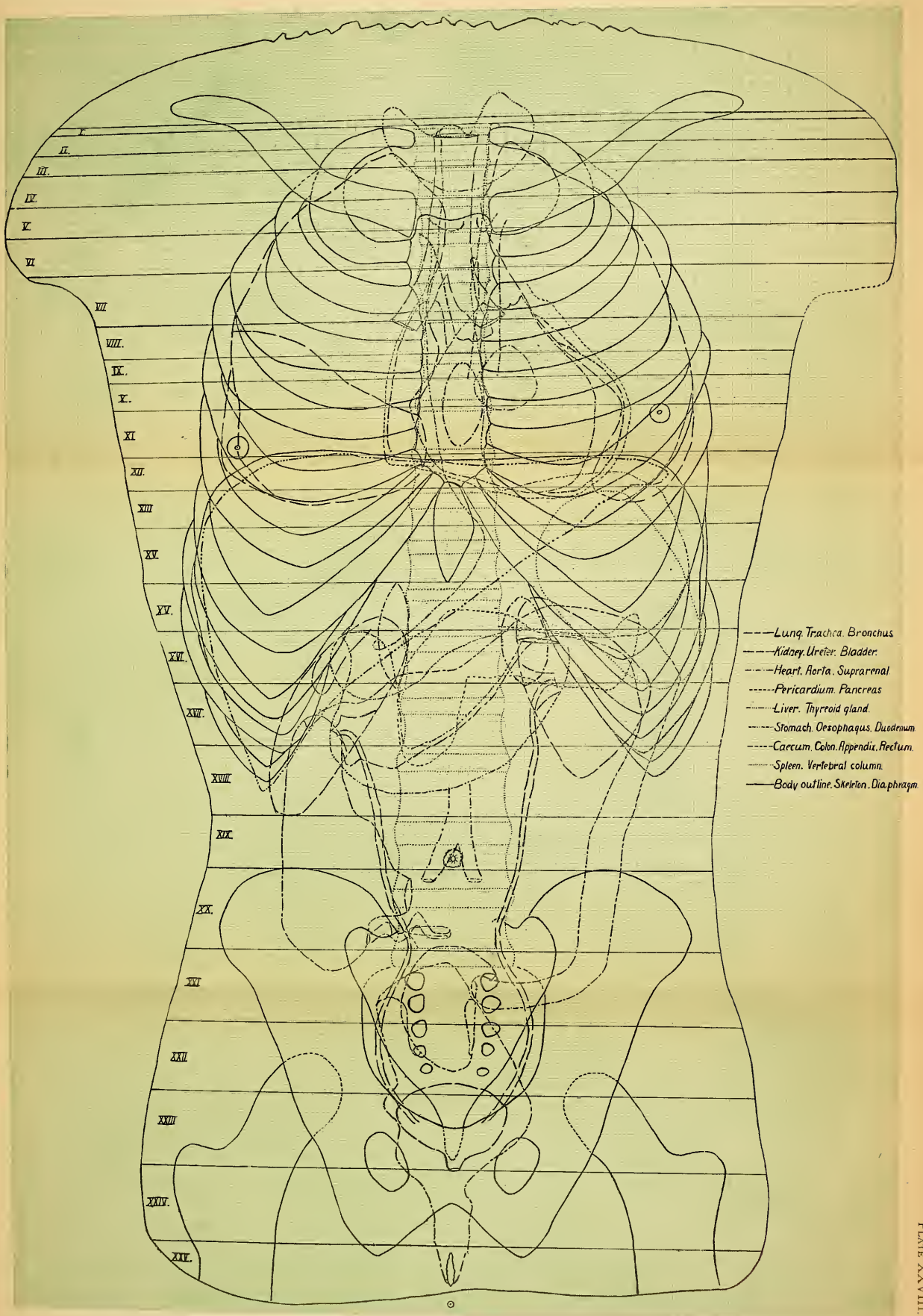
I.
II.
III.
IV.
V.
VI.
VII.
VIII.
IX.
X.
XI.
XII.
XIII.
XIV.
XV.
XVI.
XVII.
XVIII.
XIX.
XX.
XXI.
XXII.
XXIII.
XXIV.
XXV.
Lung. Trachea. Bronchus.
Kidney. Ureter. Bladder.
Heart. Aorta. Suprarenal
Pericardium. Pancreas
Liver. Thyreoid gland.
Stomach. Oesophagus. Duodenum.
Caecum. Colon. Appendix. Rectum.
Spleen. Vertebral column.
Body outline. Skeleton. Diaphragm.

PLATE XXIX

PLATE XXIX

Plate XXIX represents a projection of the same structures upon the posterior surface of the body, also reduced to one-half life size. The body outline was obtained in the same way as in Plate XXVIII. The section lines correspond to those in Plate XXVII and were located in the same way as those in Plate XXVIII. The positions of the section lines are not exactly the same in this plate as in Plate XXVIII since many of the sections differ in thickness at their anterior and posterior surfaces.

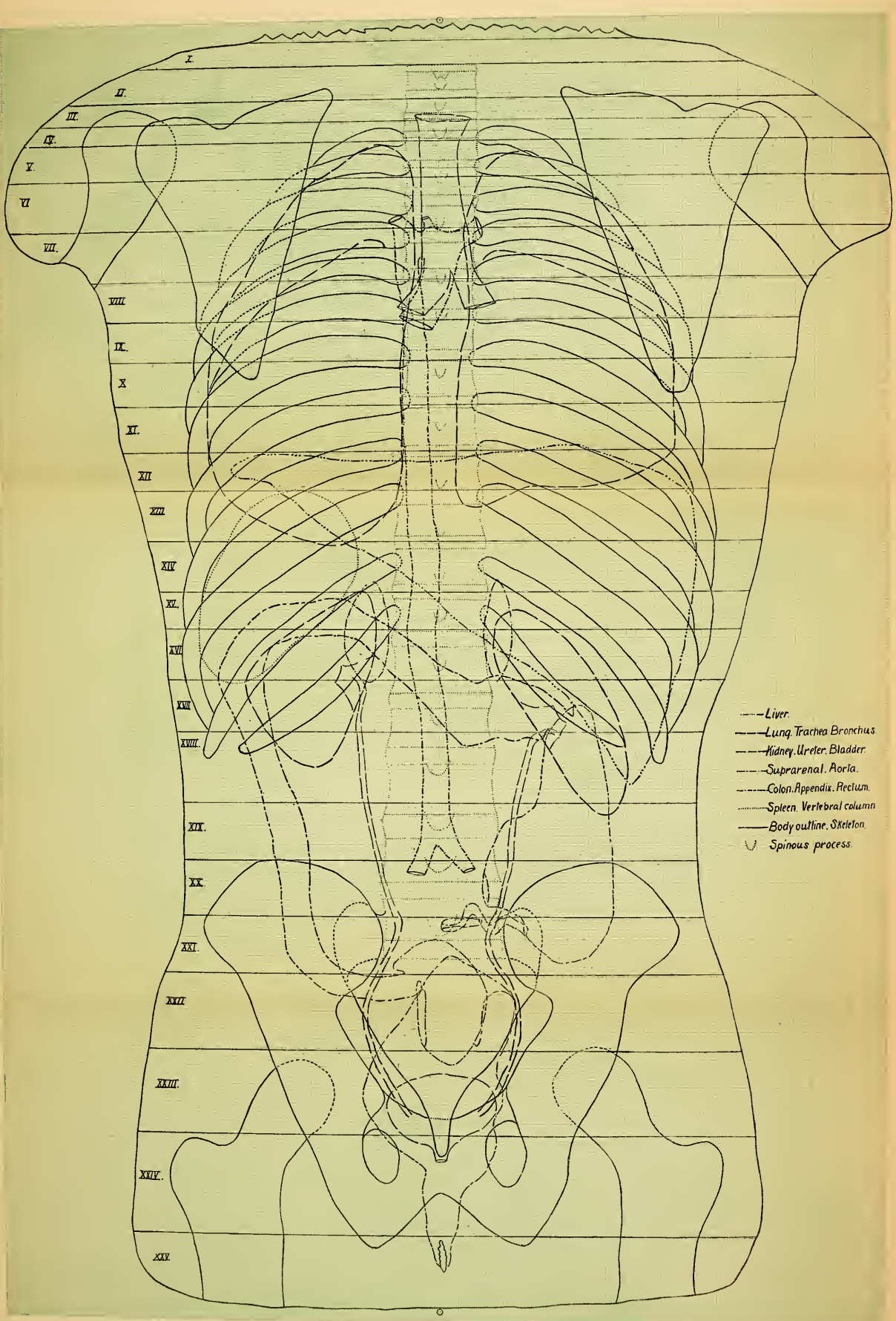
I.
II.
III.
IV.
V.
VI
VII.
VIII.
IX.
X
XI.
XII
XIII.
XIV
XV.
XVI.
XVII
XVIII.
XIX.
XX.
XXI.
XXII
XXIII.
XXIV.
XXV.
Liver.
Lung. Trachea Bronchus
Kidney. Ureter. Bladder
Suprarenal. Aorta.
Colon. Appendix. Rectum.
Spleen. Vertebral column
Body outline. Skeleton.
Spinous process.

PLATE XXX

PLATE XXX

Plate XXX represents a projection of the internal structures upon the right lateral surface of the body reduced to one-half life size. The OO line is the mid-axillary line which was determined by placing the sections in their normal positions, as in obtaining Plates XXVI and XXVII, and drawing a vertical line down through the middle of the axilla. The section lines correspond to those seen in the preceding plates.

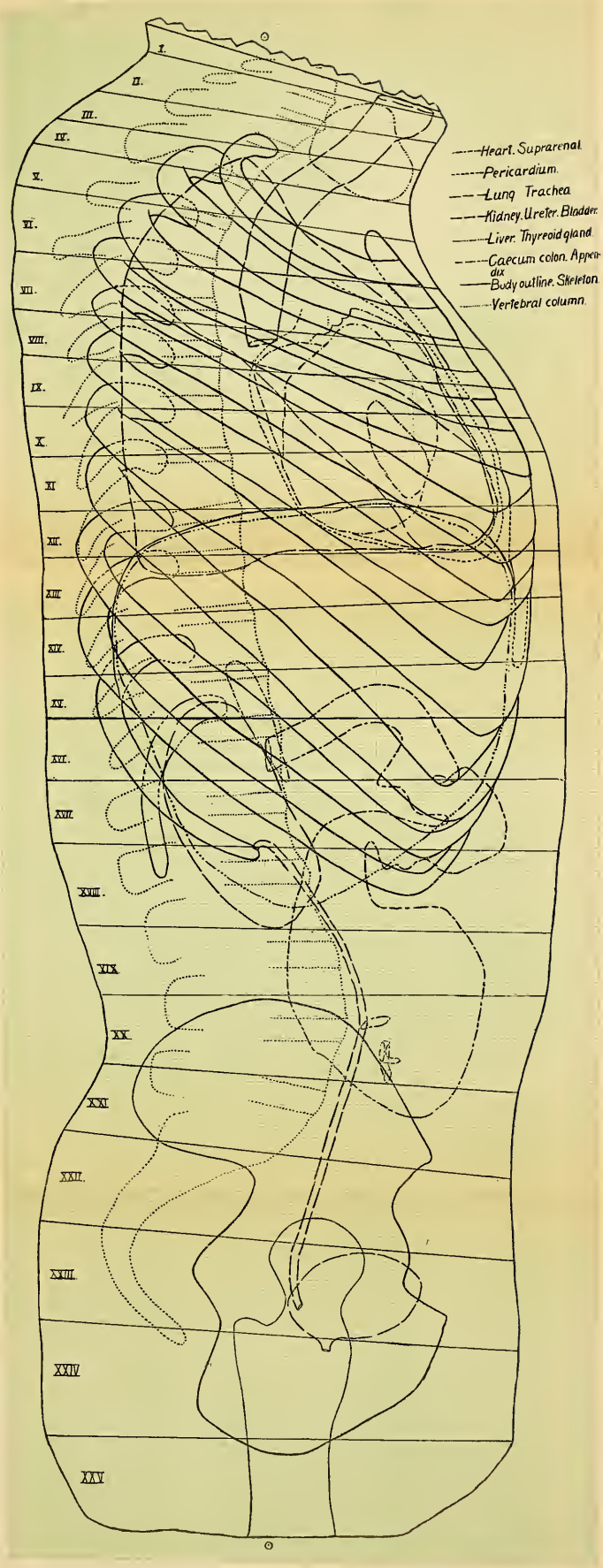
I.
II.
III.
IV.
V.
VI.
VII.
VIII.
IX.
X.
XI
XII.
XIII
XIV.
XV.
XVI.
XVII.
XVIII.
XIX.
XX.
XXI
XXII.
XXIII.
XXIV
XXV
Heart. Suprarenal.
Pericardium.
Lung Trachea.
Kidney. Ureter. Bladder.
Liver. Thyreoid gland.
Caecum colon. Appendix
Body outline. Skeleton.
Vertebral column.

PLATE XXX.

PLATE XXXI

PLATE XXXI

Plate XXXI represents a projection of the same structures upon the left lateral surface of the body, also reduced to one-half life size. The OO line in this plate is the left midaxillary line.

The measurements for the lateral projections were made in the same way as for the anterior and posterior, using the midaxillary plane instead of the midplane. In this case, however, it was not necessary to make corrections for the obliquity of the surfaces, except in one or two cases. Each organ is outlined in the same character of line in the lateral projections as in the anterior and posterior projections.

The ruled lines of the green background in Plates XXVIII to XXXI represent the millimeter spaces on the life size chart, reduced to the same scale as the figures.

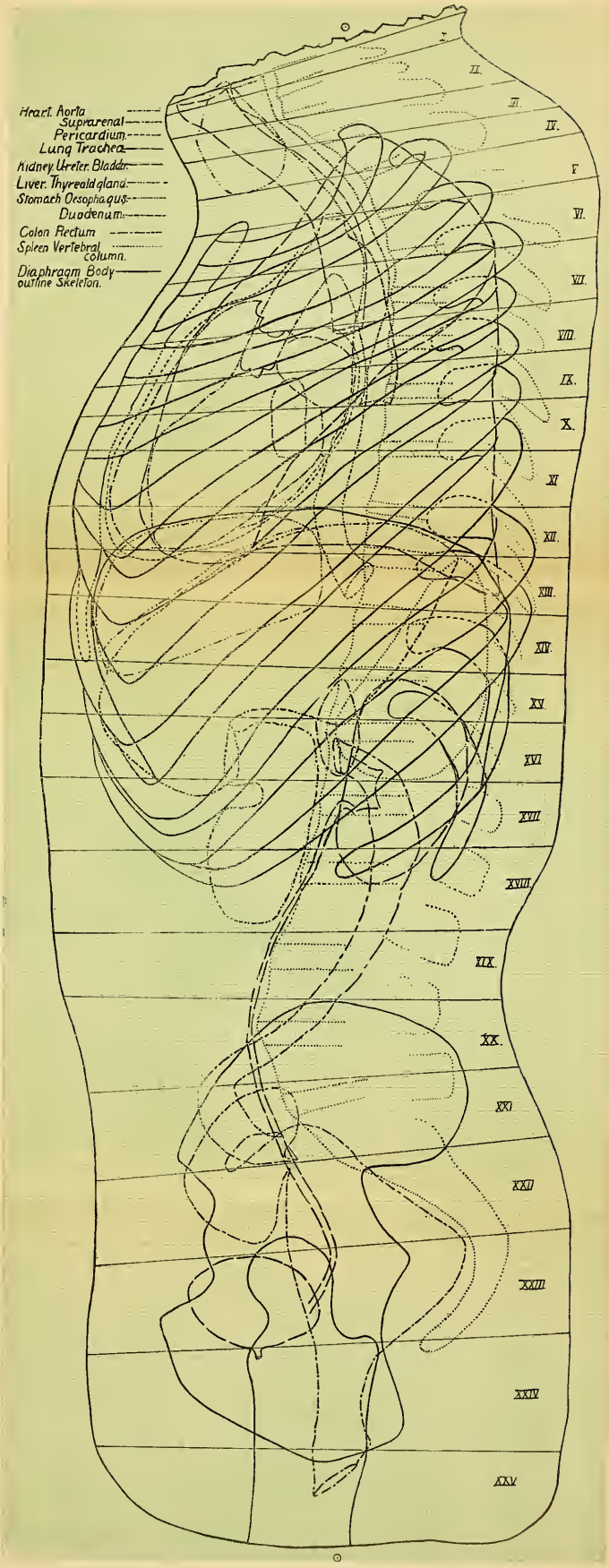
Heart. Aorta
Suprarenal
Pericardium
Lung Trachea
Kidney. Ureter. Bladder
Liver. Thyreoid gland
Stomach Oesophagus
Duodenum
Colon Rectum
Spleen Vertebral column.
Diaphragm Body outline Skeleton.
II.
III.
IV.
V
VI.
VII.
VIII.
IX.
X.
XI
XII.
XIII.
XIV.
XV.
XVI
XVII
XVIII.
XIX.
XX.
XXI
XXII
XXIII
XXIV
XXV

PLATE XXXI.

PLATE XXXII

PLATE XXXII

Plate XXXII is a reduced copy in colors of Plate XXVIII which represents the organs as projected upon the anterior surface of the body.

This Plate and the three following Plates are all reduced to about one-fourth life size. In order to bring out more clearly the intricate relations of the various organs shown in outline in Plates XXVIII to XXXI each organ is shown in a distinctive color in Plates XXXII to XXXV. The colors used for the various organs are indicated on the plates.

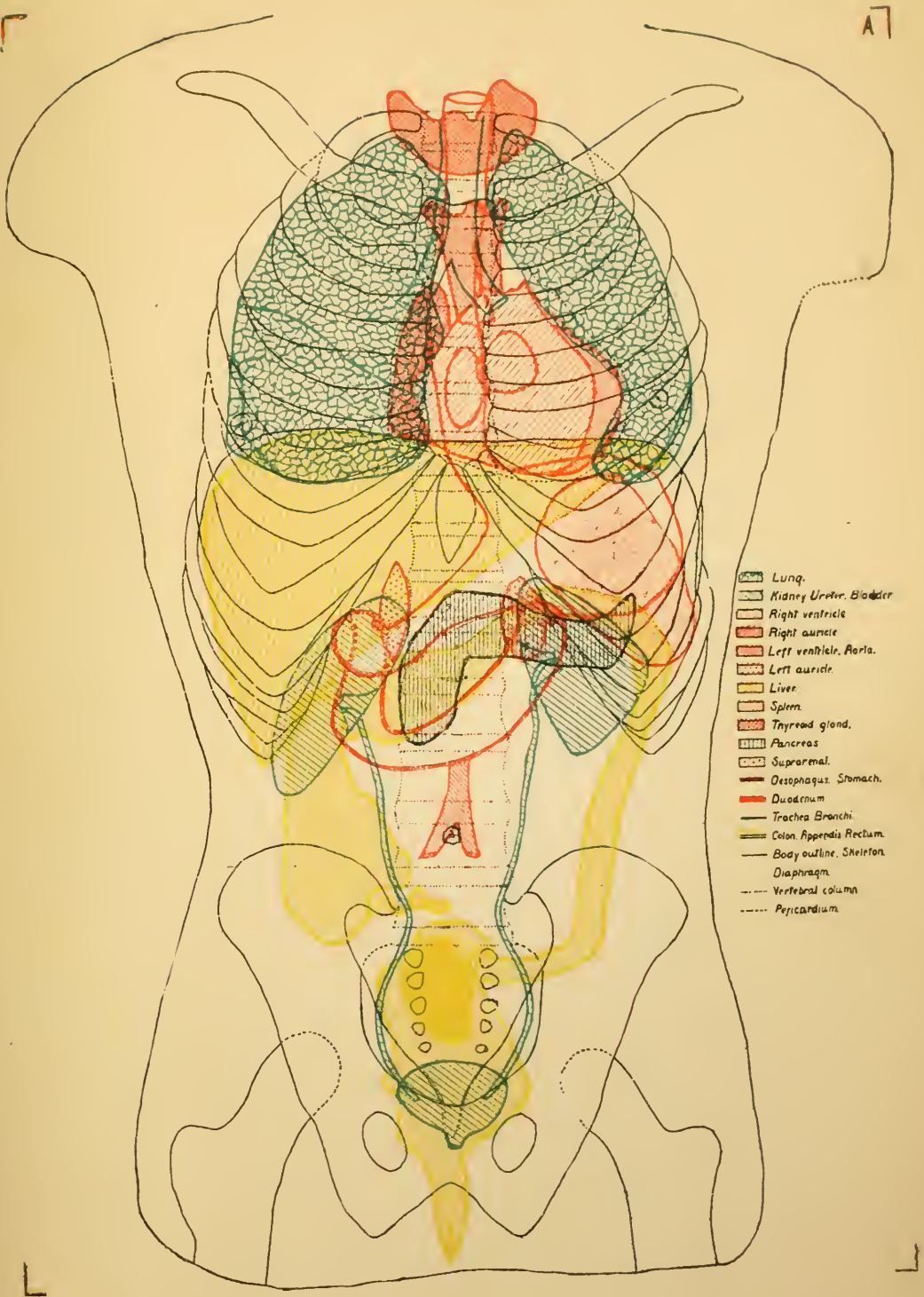
Lung.
Kidney Ureter. Bladder
Right ventricle
Right auricle
Left ventricle. Aorta.
Left auricle.
Liver
Spleen
Thyreoid gland.
Pancreas
Suprarenal.
Oesophagus. Stomach.
Duodenum
Trachea Bronchi.
Colon. Appendix Rectum.
Body outline. Skeleton.
Diaphragm.
Vertebral column
Pericardium.

PLATE XXXIII

PLATE XXXIII

Plate XXXIII is a reduced copy in colors of Plate XXIX which represent the organs as projected upon the posterior surface of the body. One-fourth life size.

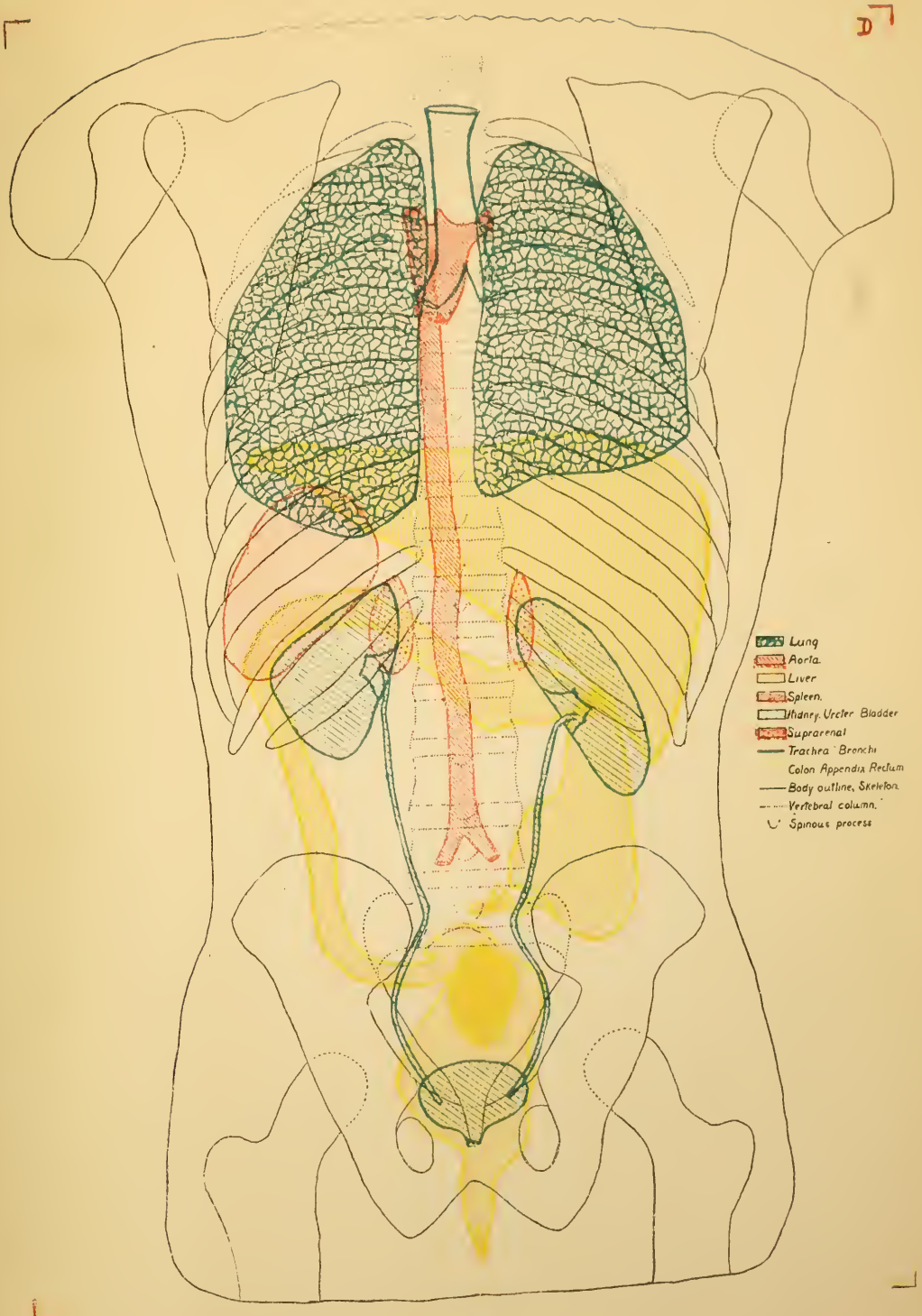
D
Lung
Aorta.
Liver
Spleen.
Kidney. Ureter Bladder
Suprarenal
Trachea Bronchi
Colon Appendix Rectum
Body outline, Skeleton
Vertebral column.
Spinous process

PLATE XXXIV

PLATE XXXIV

Plate XXXIV is a reduced copy in colors of Plate XXX which represents the organs projected upon the right lateral surface of the body. One-fourth life size.

B
Left auricle
Lung
Right auricle
Right ventricle
Liver
Kidney Ureter.
Bladder.
Suprarenal
Thyroid gland.
Body outline.
Skeleton.
Trachea.
Colon.
Vertebral column.
Pericardium.

PLATE XXXV

PLATE XXXV

Plate XXXV is a reduced copy in colors of Plate XXXI which represents the organs projected upon the left lateral surface of the body. One-fourth life size.

Lung
Left auricle
Left ventricle
Aorta.
Right ventricle
Liver.
Kidney Ureter.
Bladder.
Spleen
Suprarenal
Thyreoid gland
Stomach. Oesophagus
Duodenum
Colon Rectum
Body outline
Skeleton
Vertebral column.
Peri-cardium

5 W-1
7655